Capture 16

a
b

a

b

a

b

c

d

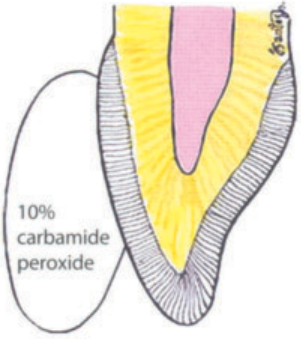
10%
carbamide
peroxide

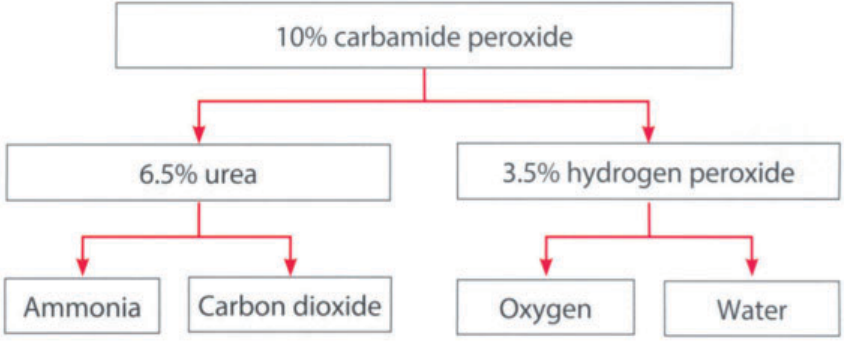
10% carbamide peroxide
6.5% urea
3.5% hydrogen peroxide
Ammonia
Carbon dioxide
Oxygen
Water

a

b

C3

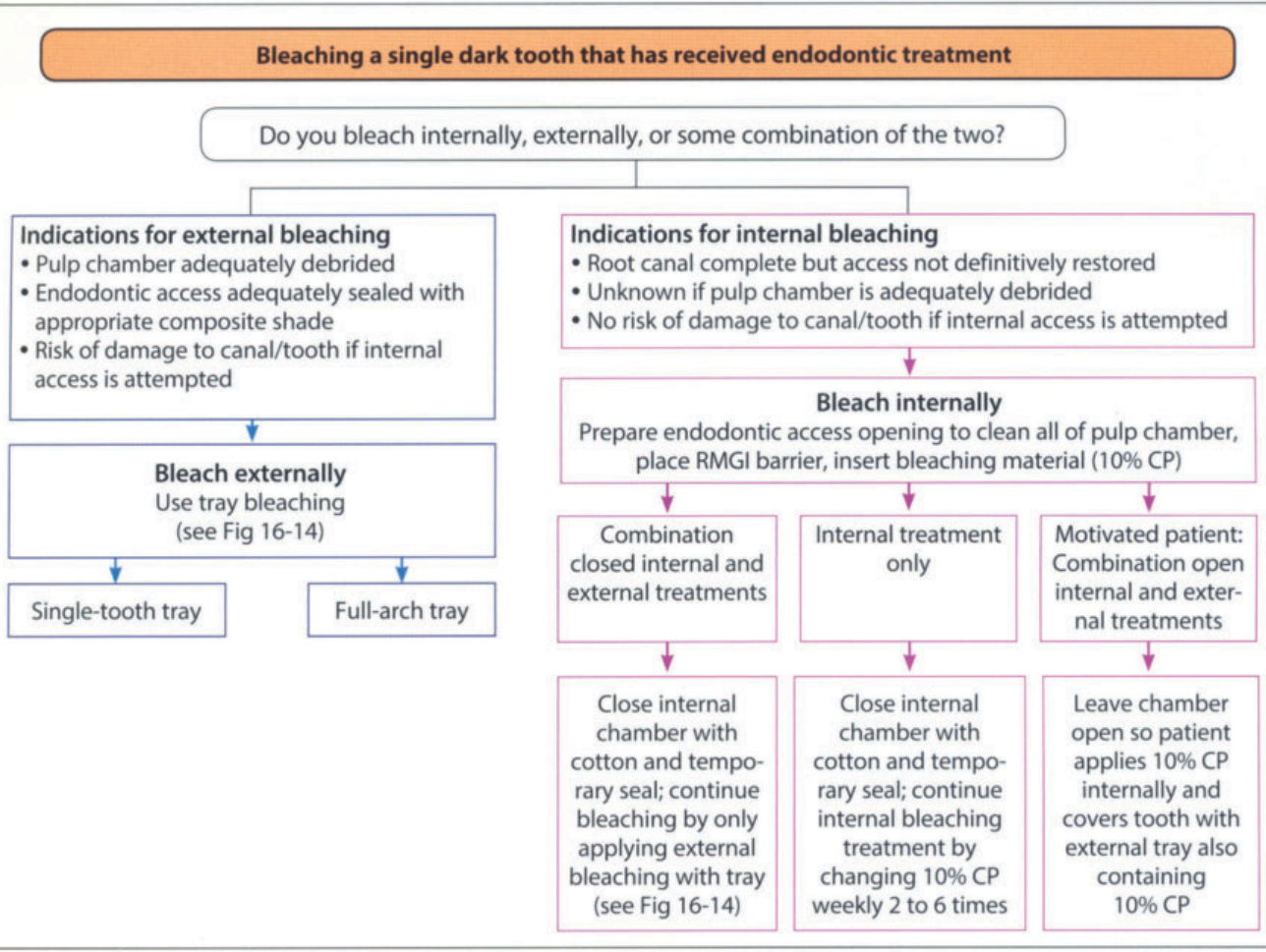
Bleaching a single dark tooth that has received endodontic treatment
Do you bleach internally, externally, or some combination of the two?
Indications for external bleaching
• Pulp chamber adequately debrided
• Endodontic access adequately sealed with appropriate composite shade
• Risk of damage to canal/tooth if internal access is attempted
Bleach externally
Use tray bleaching
(see Fig 16-14)
Single-tooth tray
Full-arch tray
Indications for internal bleaching
• Root canal complete but access not definitively restored
• Unknown if pulp chamber is adequately debrided
• No risk of damage to canal/tooth if internal access is attempted
Bleach internally
Prepare endodontic access opening to clean all of pulp chamber, place RMGI barrier, insert bleaching material (10% CP)
Combination closed internal and external treatments
Internal treatment only
Motivated patient: Combination open internal and external treatments
Close internal chamber with cotton and temporary seal; continue bleaching by only applying external bleaching with tray (see Fig 16-14)
Close internal chamber with cotton and temporary seal; continue internal bleaching treatment by changing 10% CP weekly 2 to 6 times
Leave chamber open so patient applies 10% CP internally and covers tooth with external tray also containing 10% CP

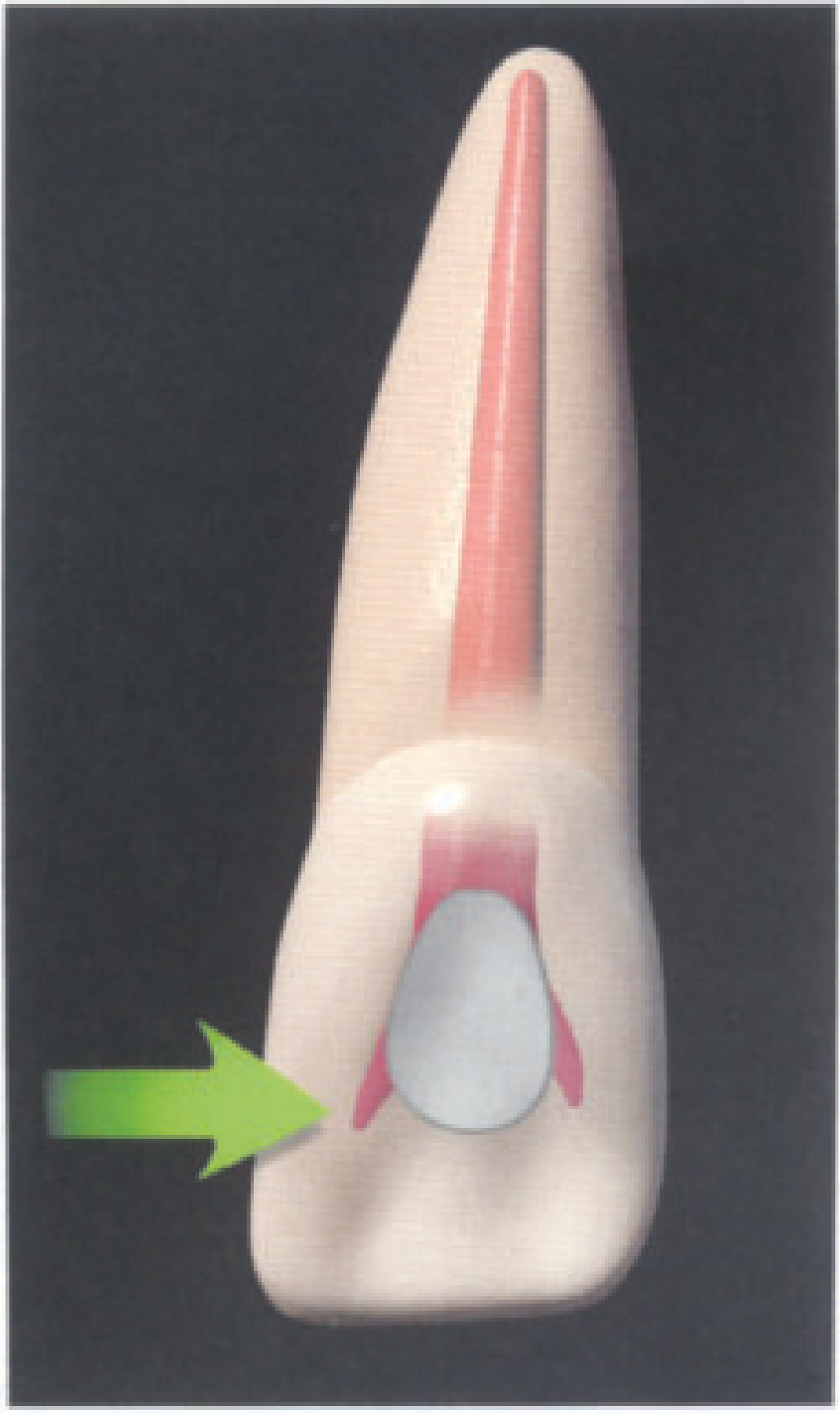

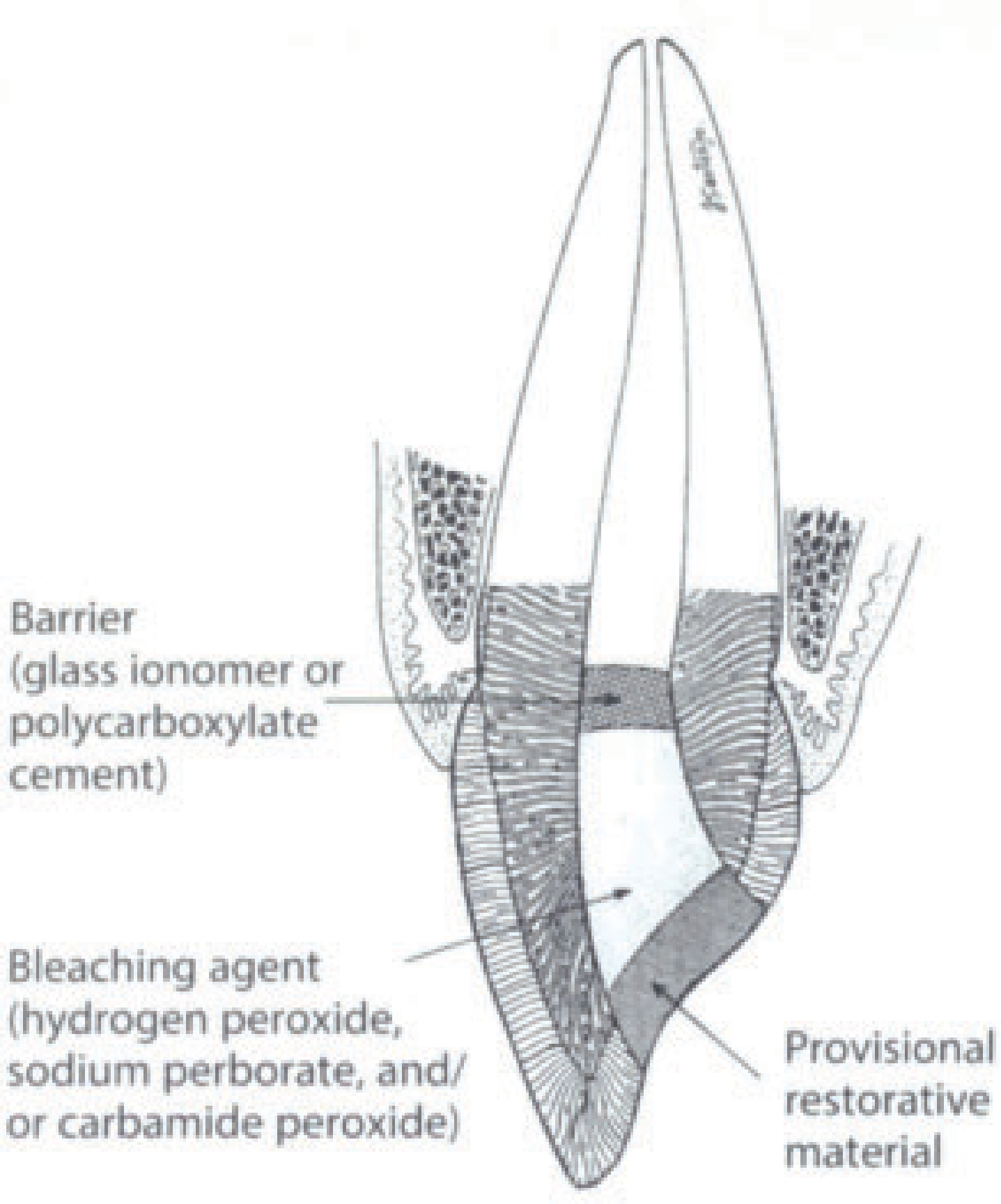
Barrier
(glass ionomer or
polycarboxylate
cement)
Bleaching agent
(hydrogen peroxide,
sodium perborate, and/
or carbamide peroxide)
Provisional
restorative
material

a

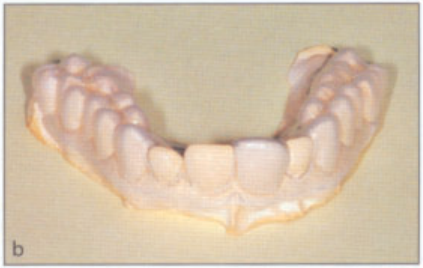
b

c

d

e

f

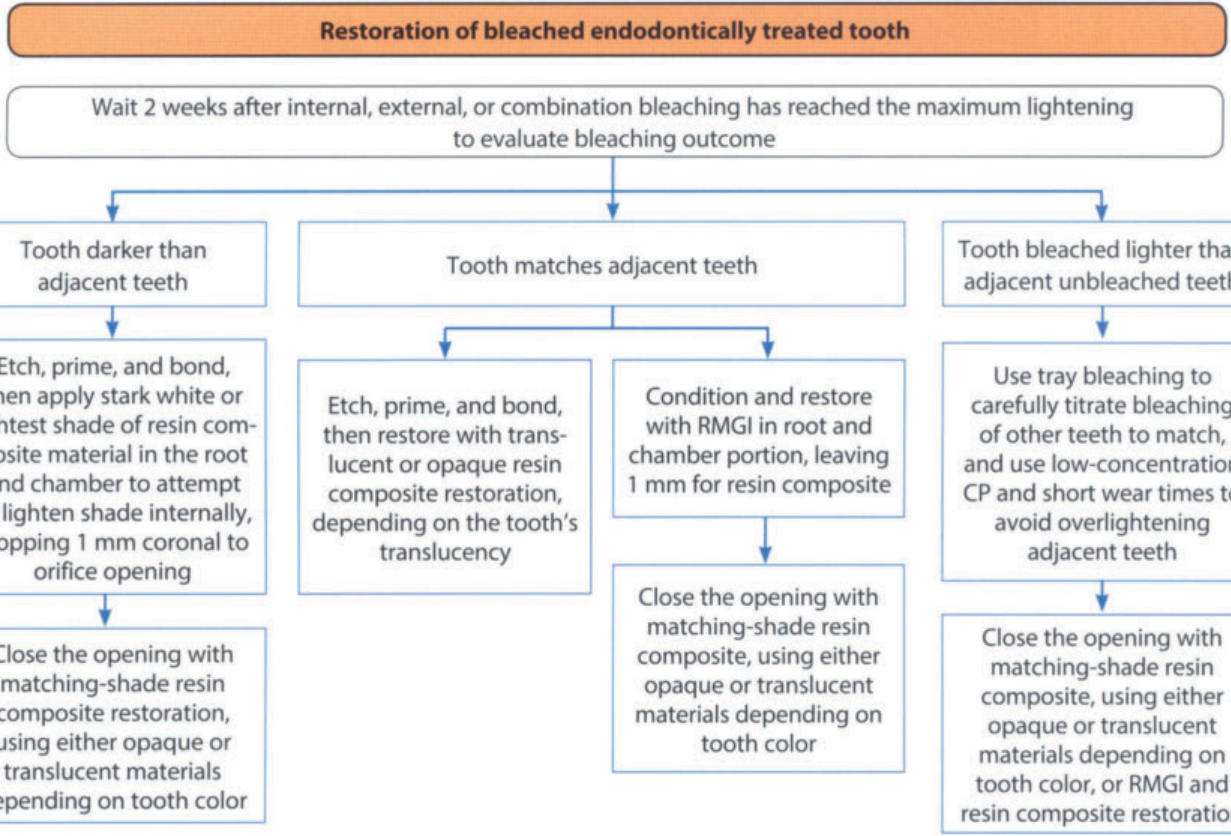
Restoration of bleached endodontically treated tooth
Wait 2 weeks after internal, external, or combination bleaching has reached the maximum lightening to evaluate bleaching outcome
Tooth darker than adjacent teeth
Tooth matches adjacent teeth
Tooth bleached lighter than adjacent unbleached teeth
Etch, prime, and bond, then apply stark white or lightest shade of resin composite material in the root and chamber to attempt to lighten shade internally, stopping 1 mm coronal to orifice opening
Close the opening with matching-shade resin composite restoration, using either opaque or translucent materials depending on tooth color
Etch, prime, and bond, then restore with translucent or opaque resin composite restoration, depending on the tooth's translucency
Condition and restore with RMGI in root and chamber portion, leaving 1 mm for resin composite
Close the opening with matching-shade resin composite, using either opaque or translucent materials depending on tooth color
Use tray bleaching to carefully titrate bleaching of other teeth to match, and use low-concentration CP and short wear times to avoid overlightening adjacent teeth
Close the opening with matching-shade resin composite, using either opaque or translucent materials depending on tooth color, or RMGI and resin composite restoration

a

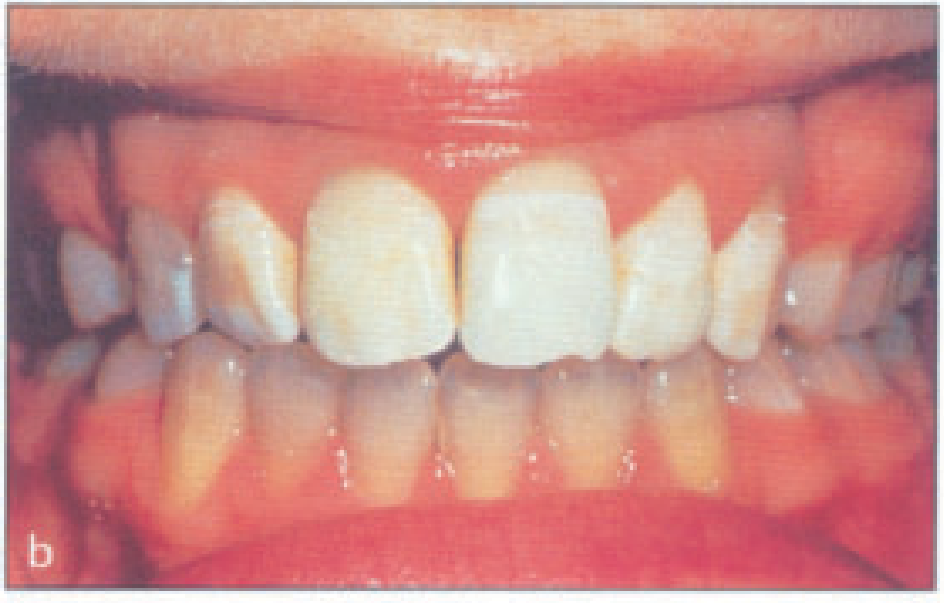
b

a
b
c

a

b

c

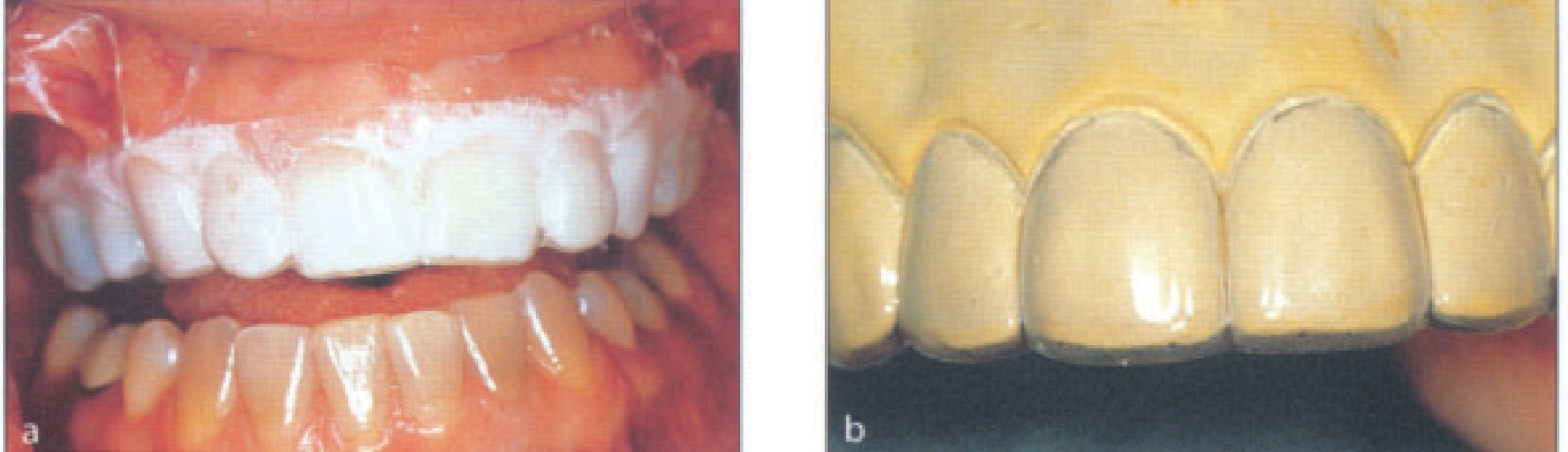
a
b

a

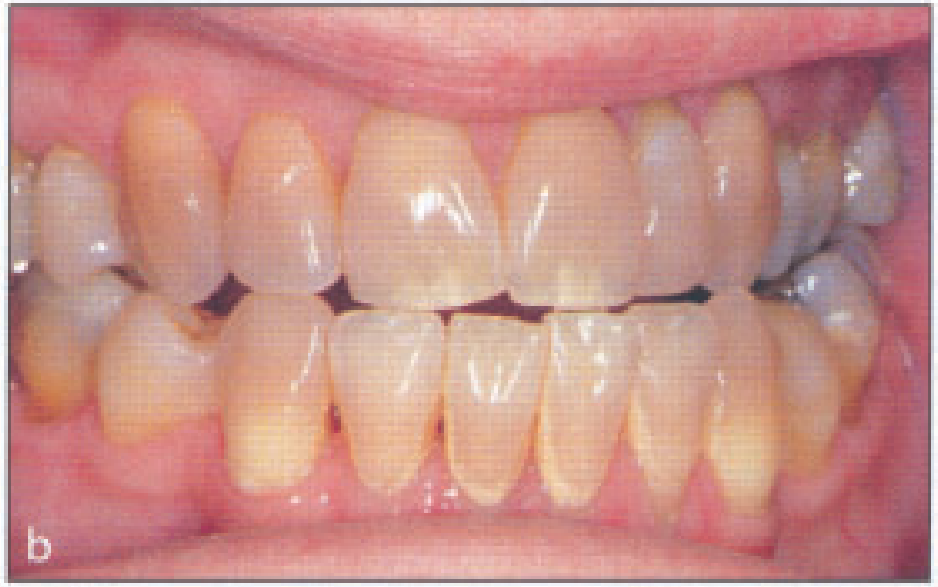
b

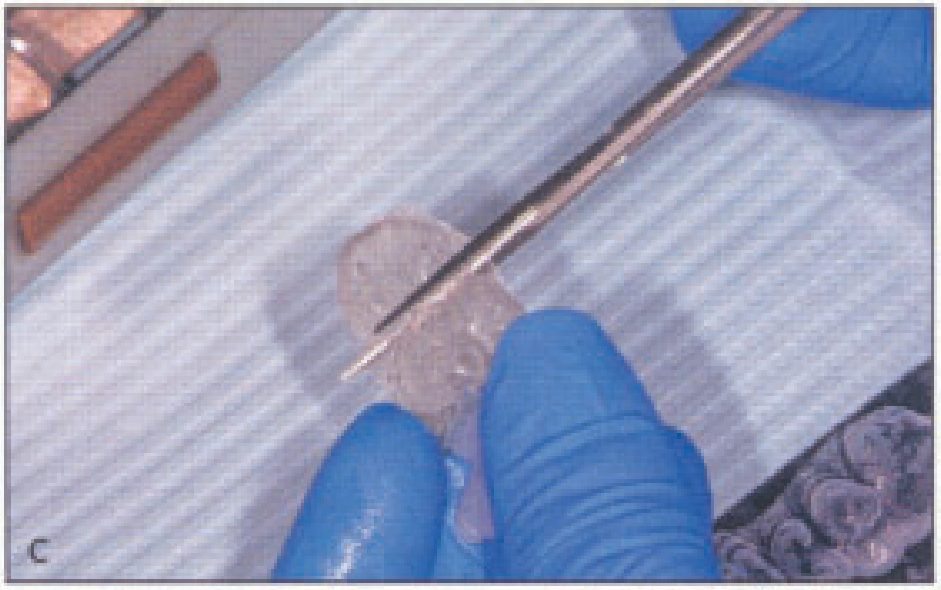
c

d

a

b

a

b

a

b

a

b

a

b

a

b

a
b
c

a
b
c

a

b

a

b

c

d

a

b

c

d

Capture 17

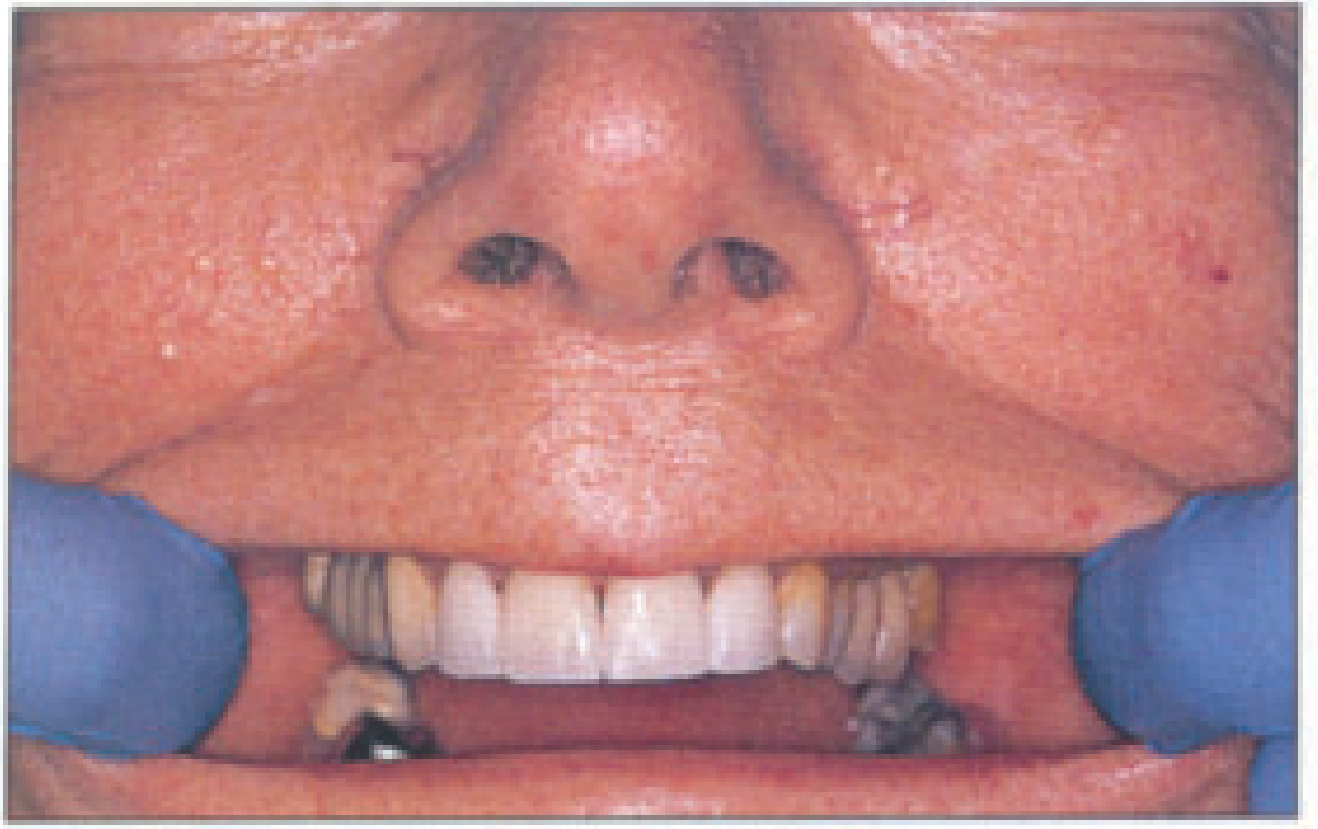

a

b

a

b

c

d

a

b

c

d

e

a
b
c
d
e
f

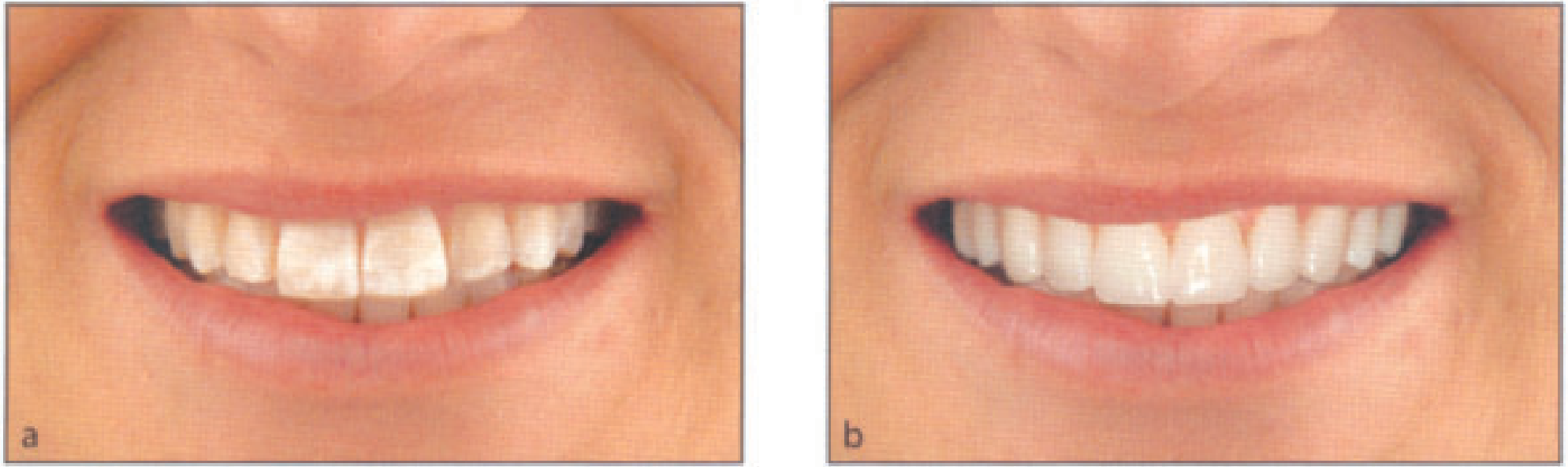
a
b

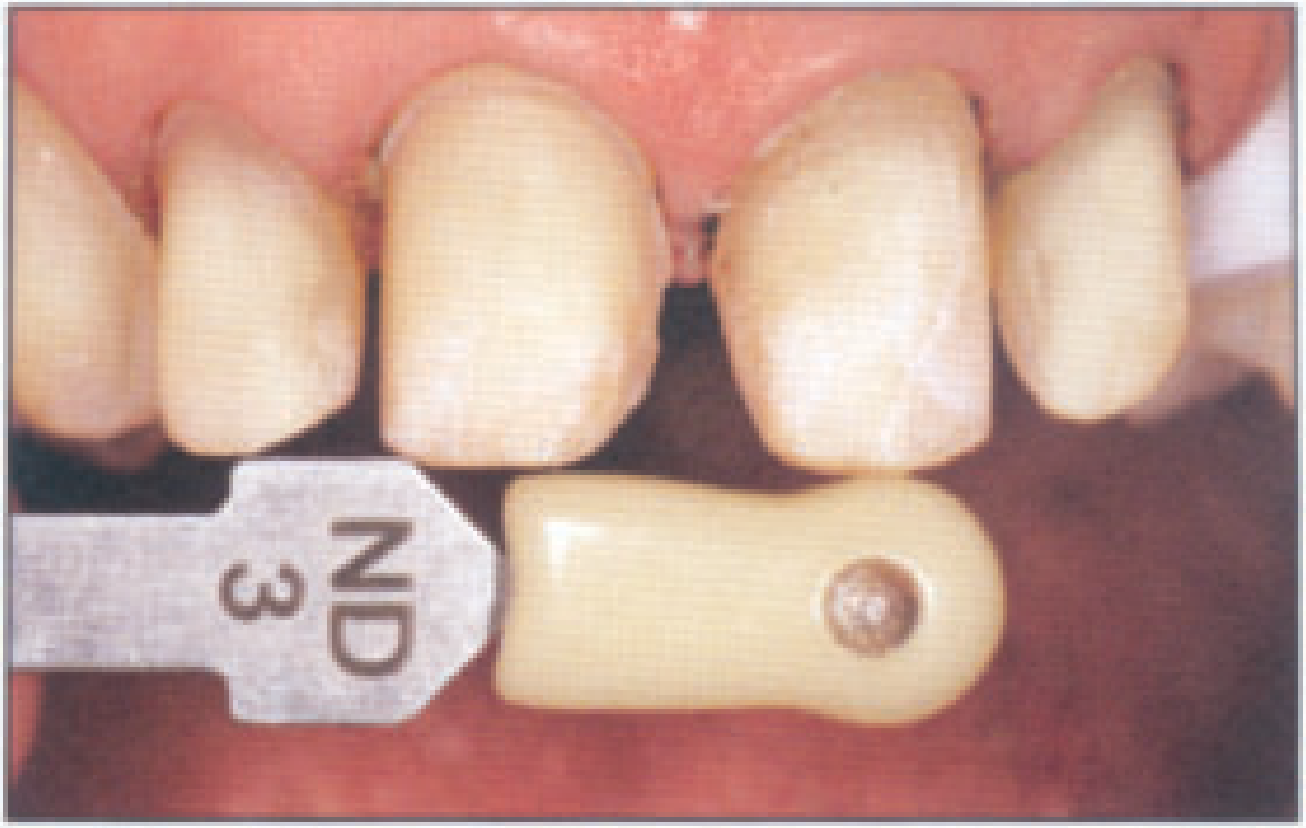
3 DN

a

b

c

d

a

b

a

b

a

b

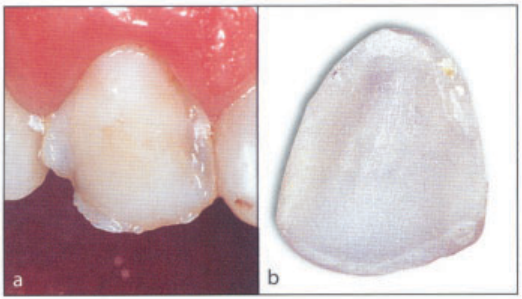
a
b
c
d

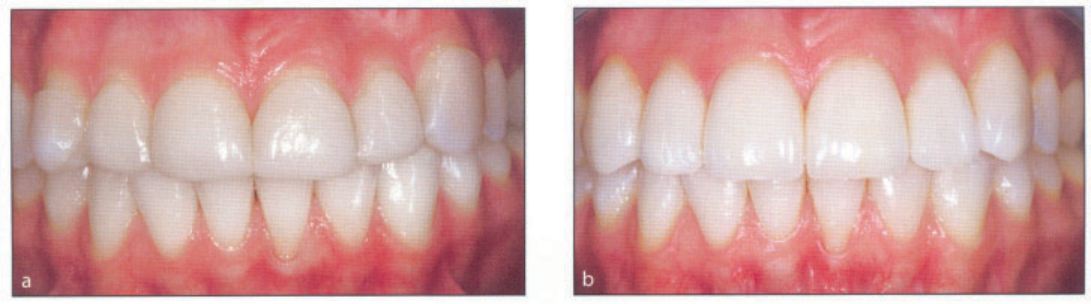
a
b

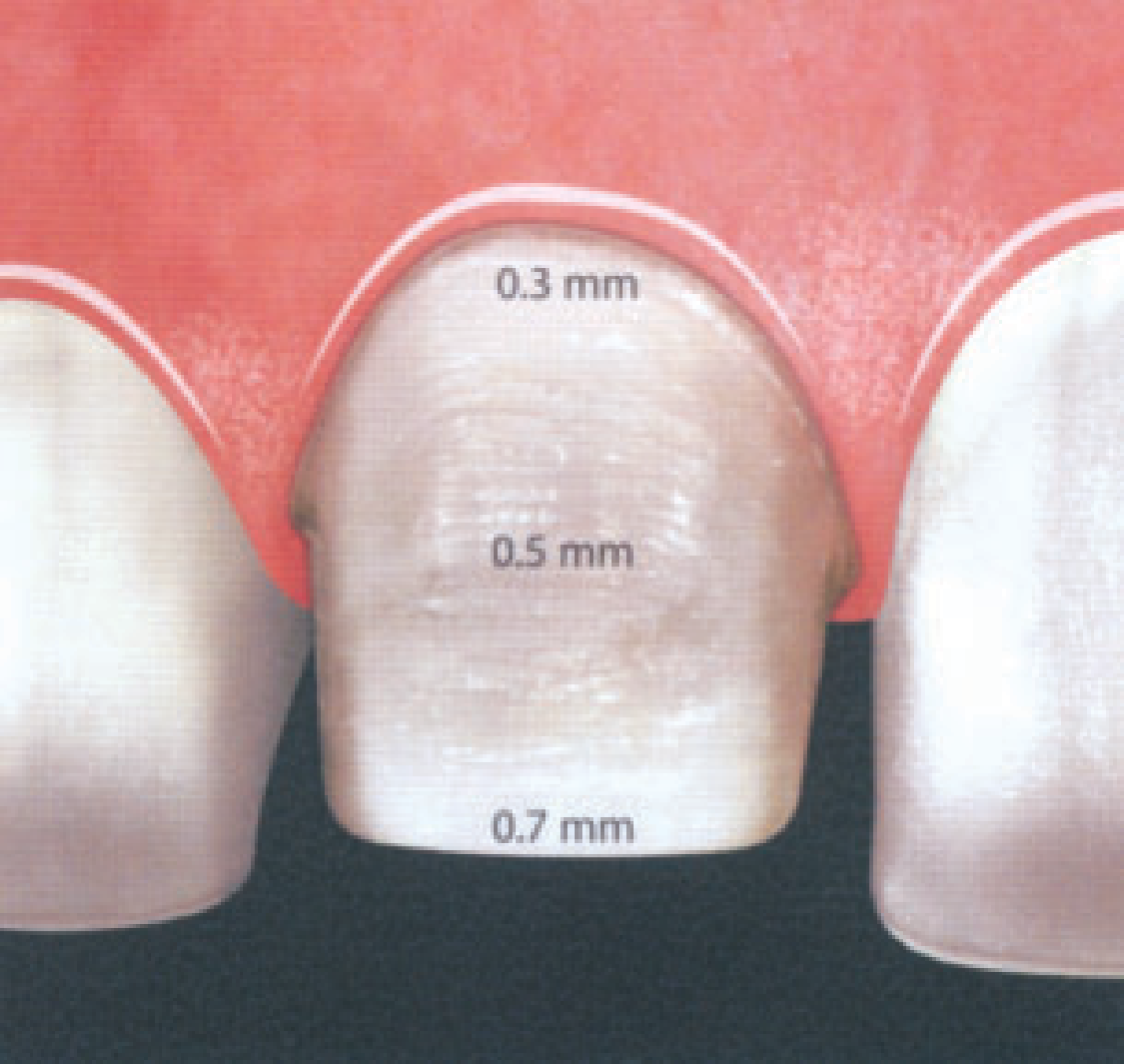
0.3 mm
0.5 mm
0.7 mm

a

b

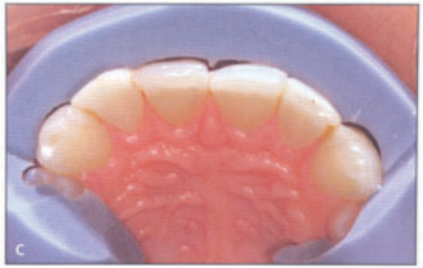
c

a

b

c

d

e

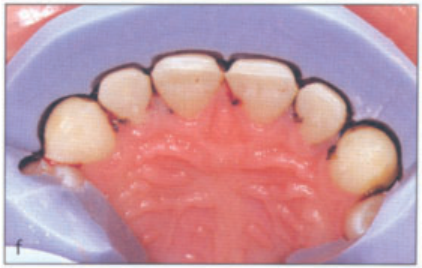
f

g

h

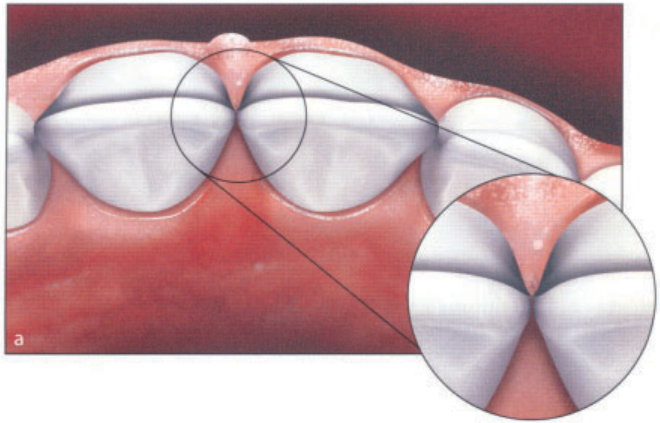
a

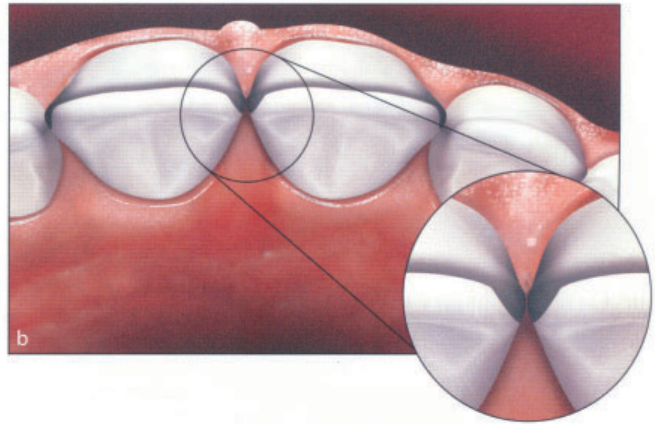
b

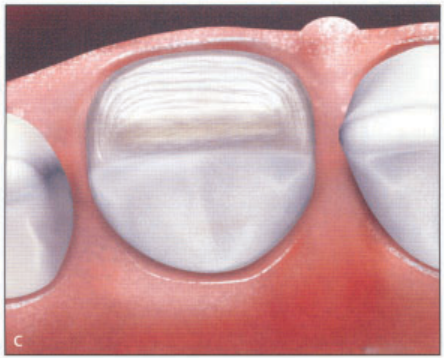
c

a

b

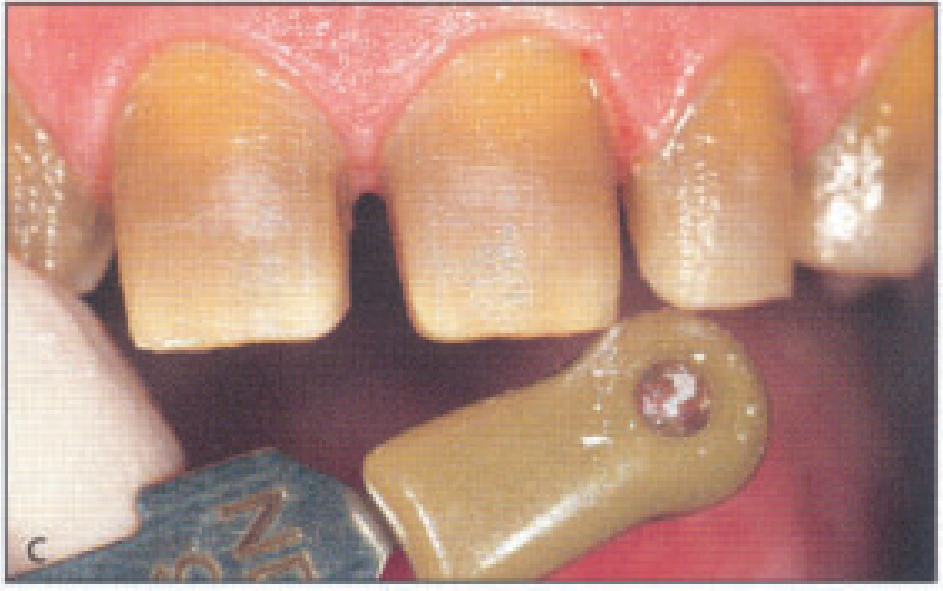
c

d

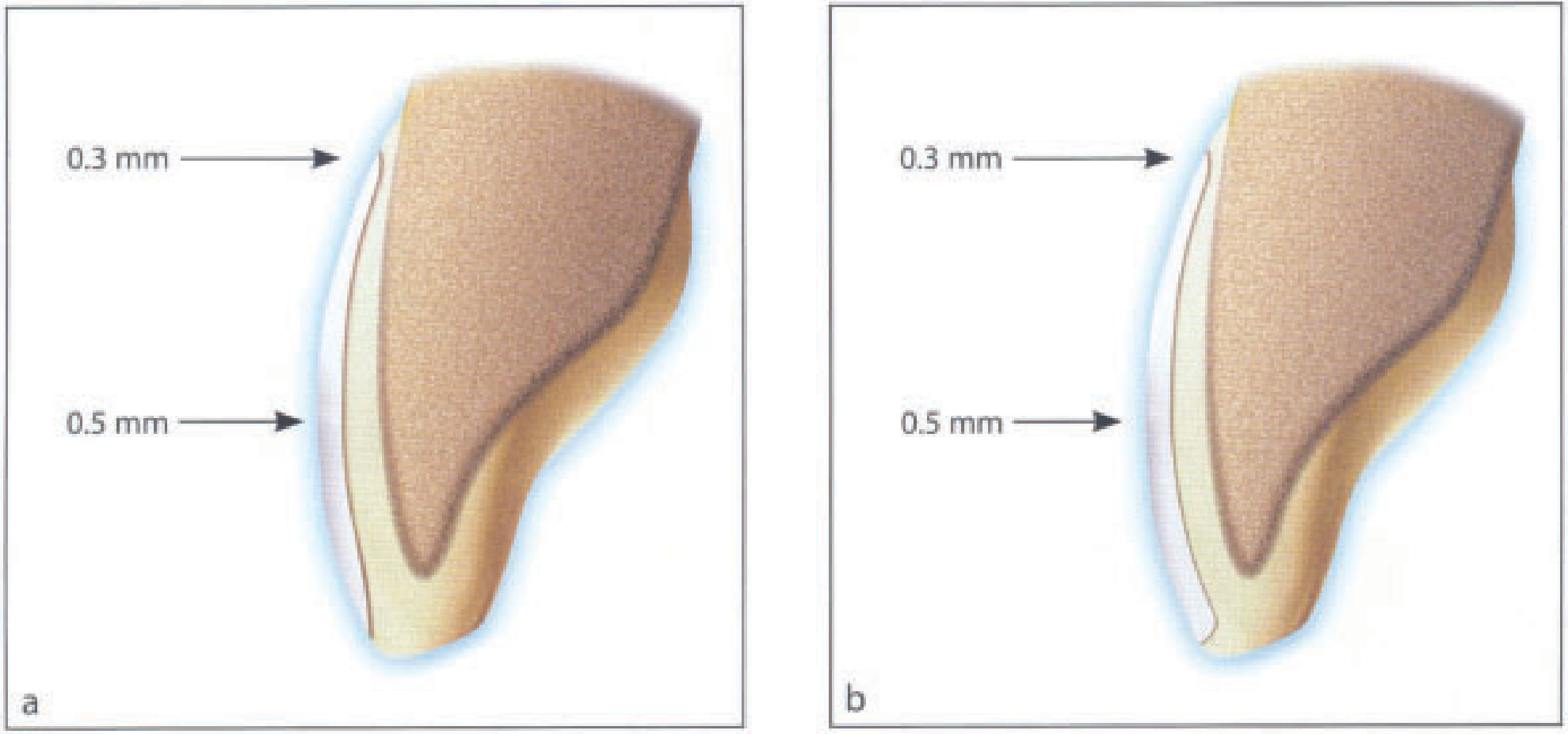
0.3 mm
0.5 mm
a
0.3 mm
0.5 mm
b

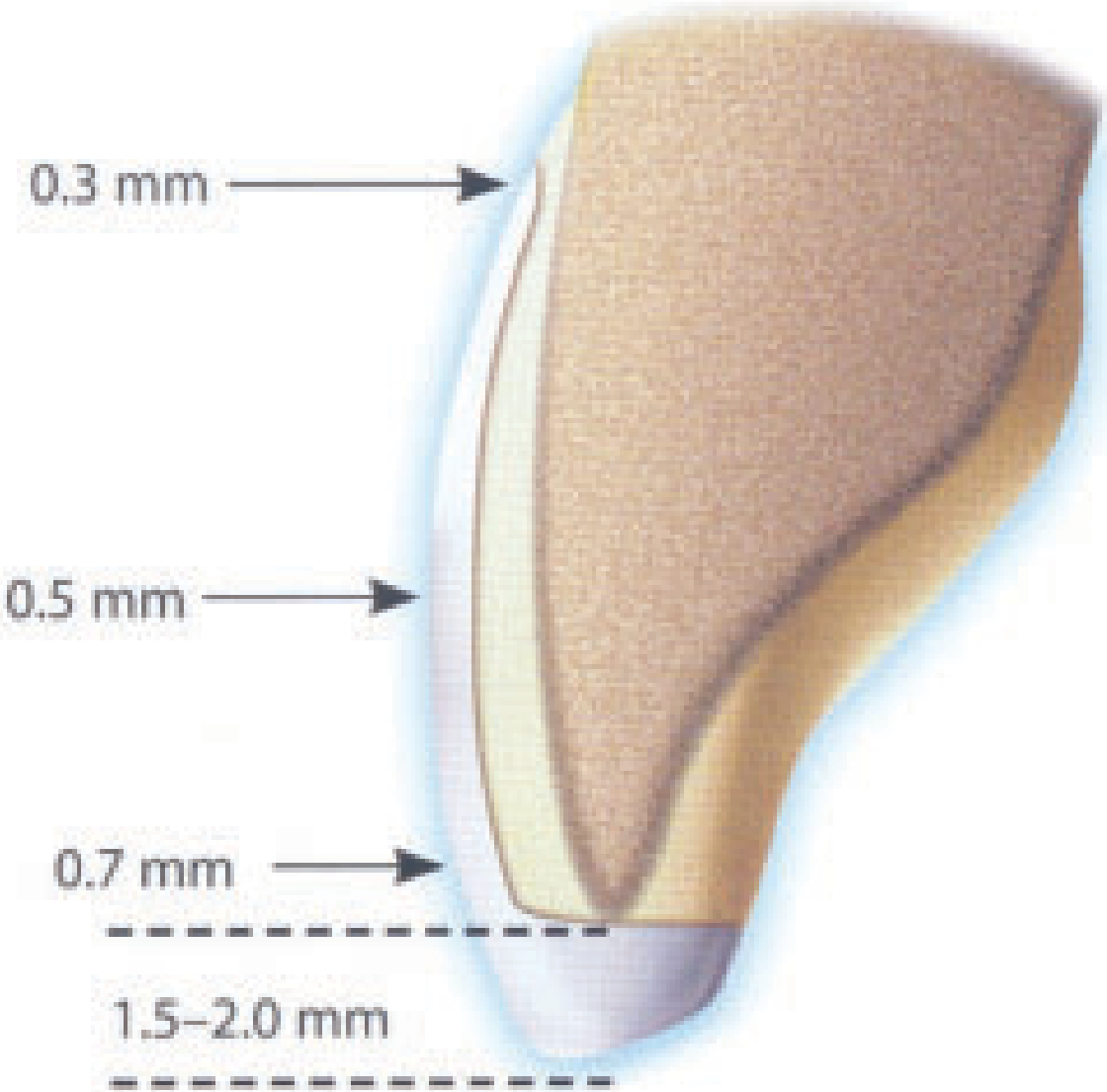
0.3 mm
0.5 mm
0.7 mm
1.5–2.0 mm

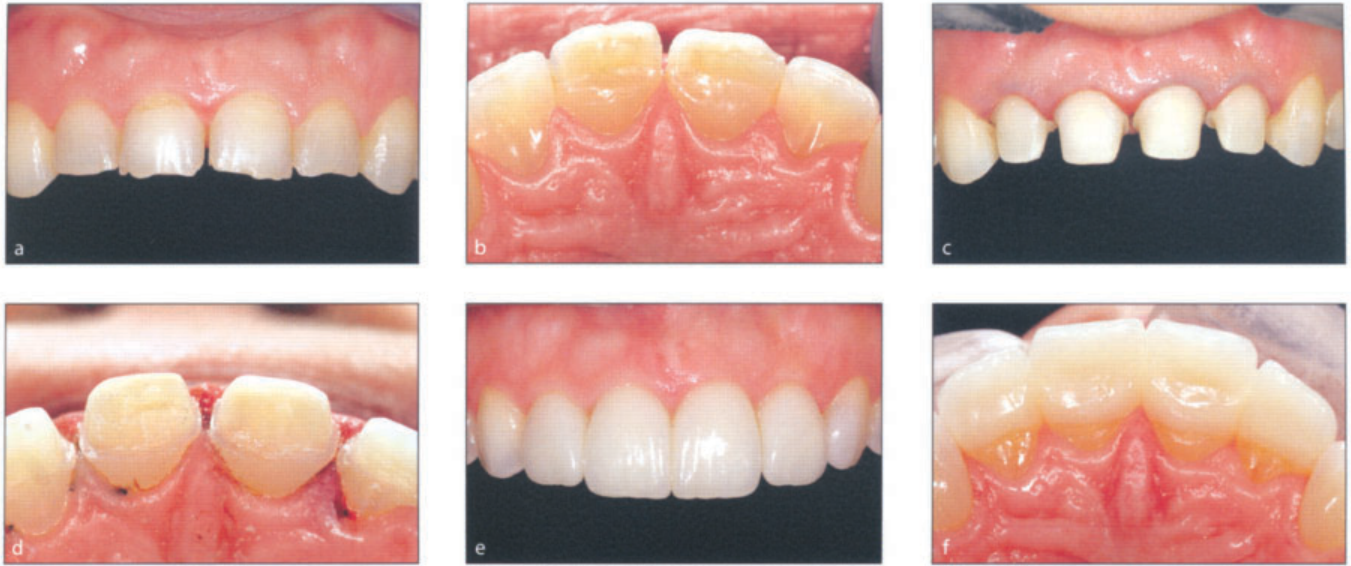
a
b
c
d
e
f

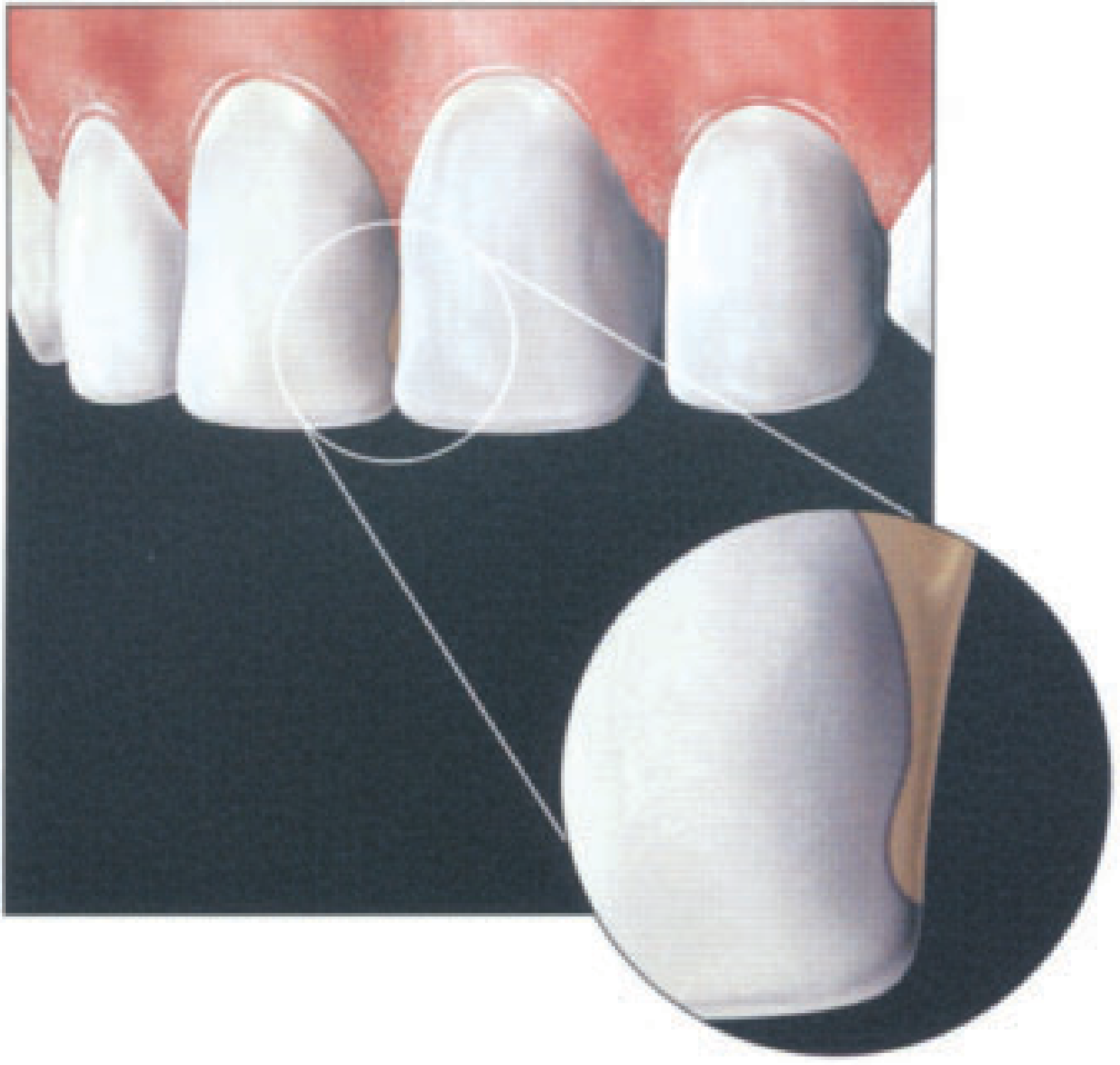

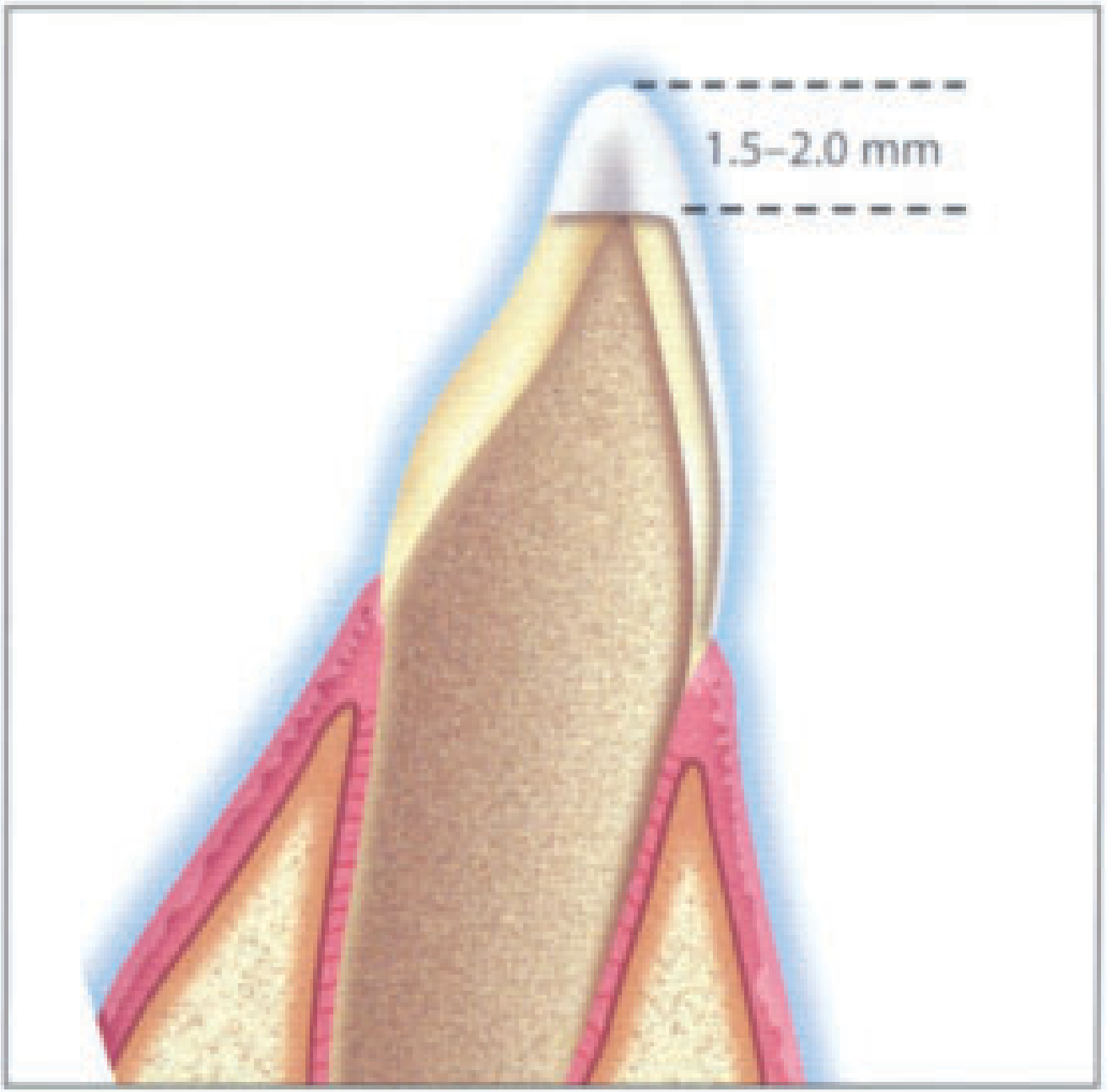
1.5–2.0 mm

a

b

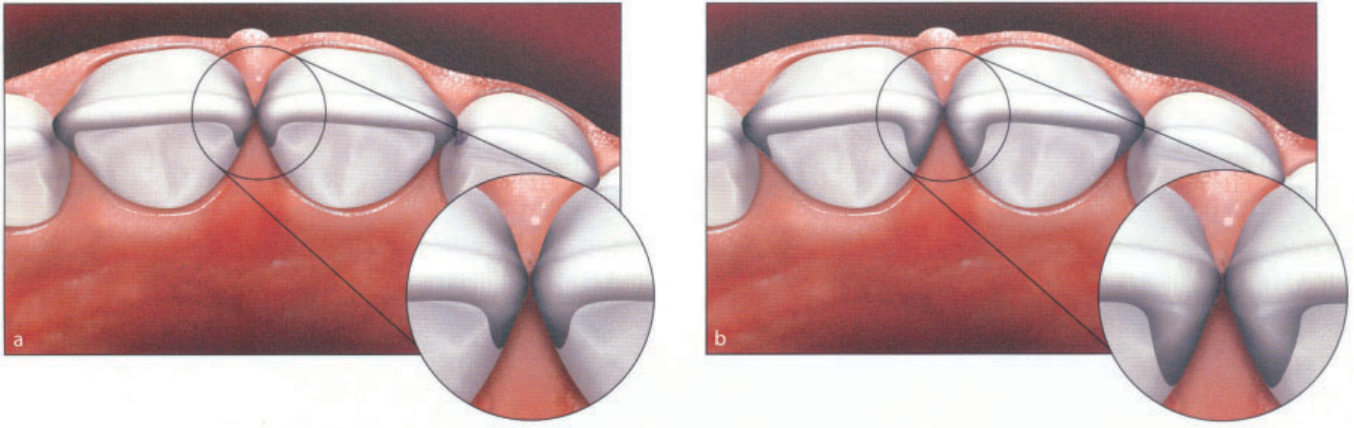
a
b

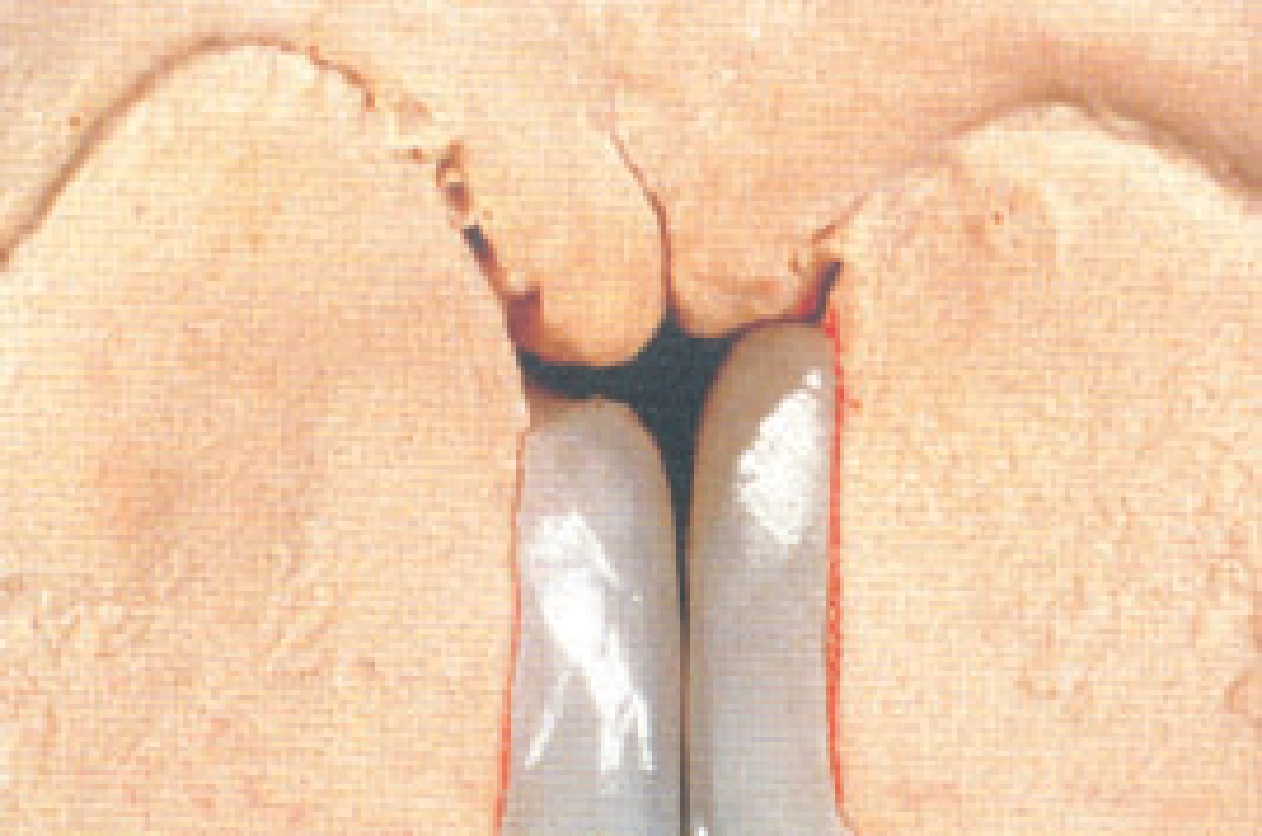

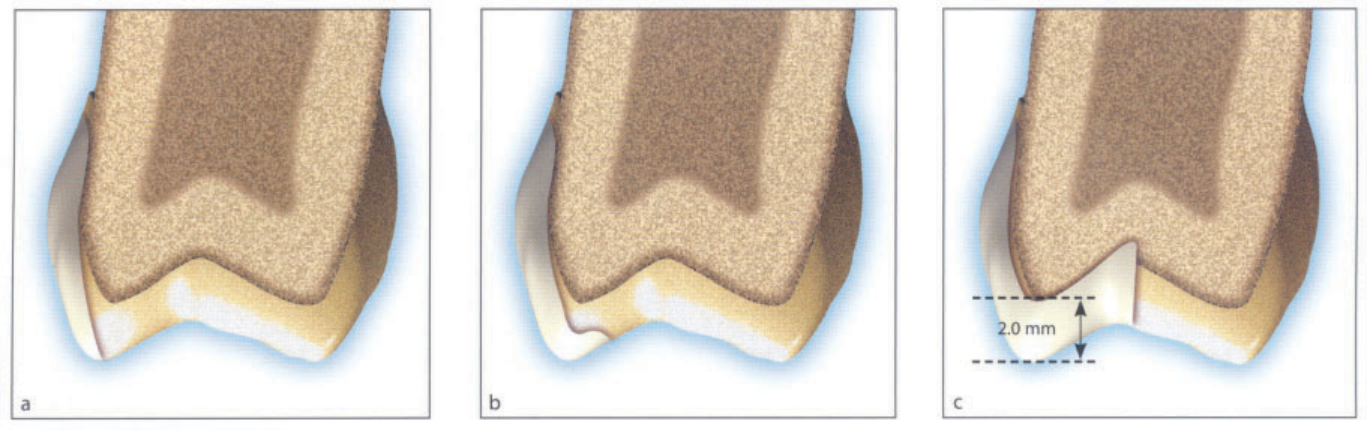
a
b
2.0 mm
c

a

b

a

b

c

d

e

a
b
c

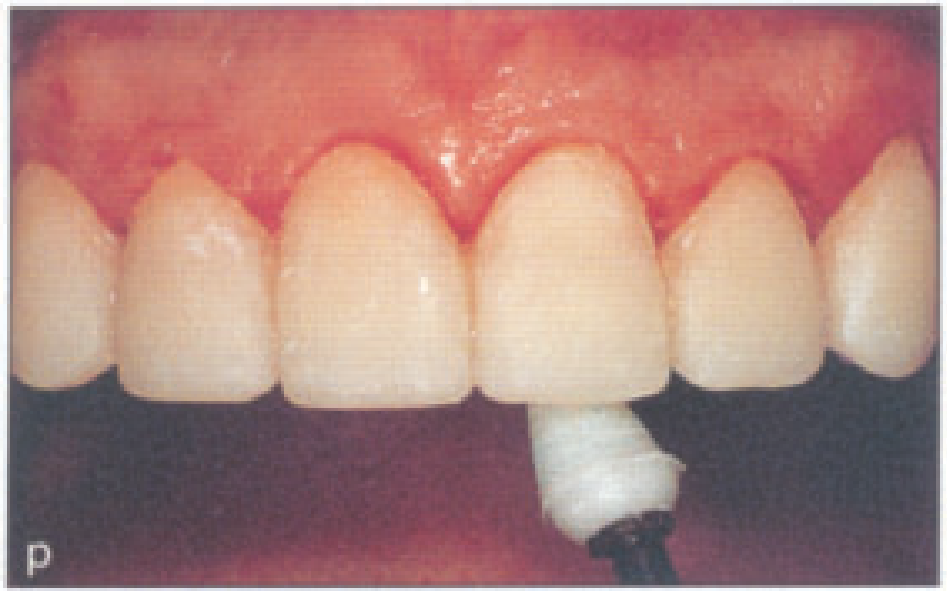
p

q

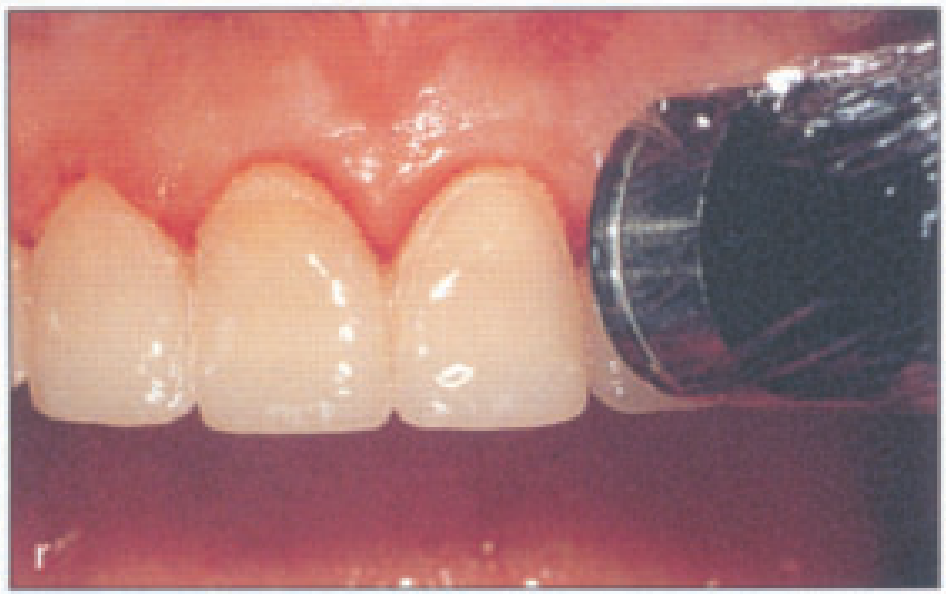
r

s

a
b
c
d
e
f
g
h
i
j
k
l
m
n
o

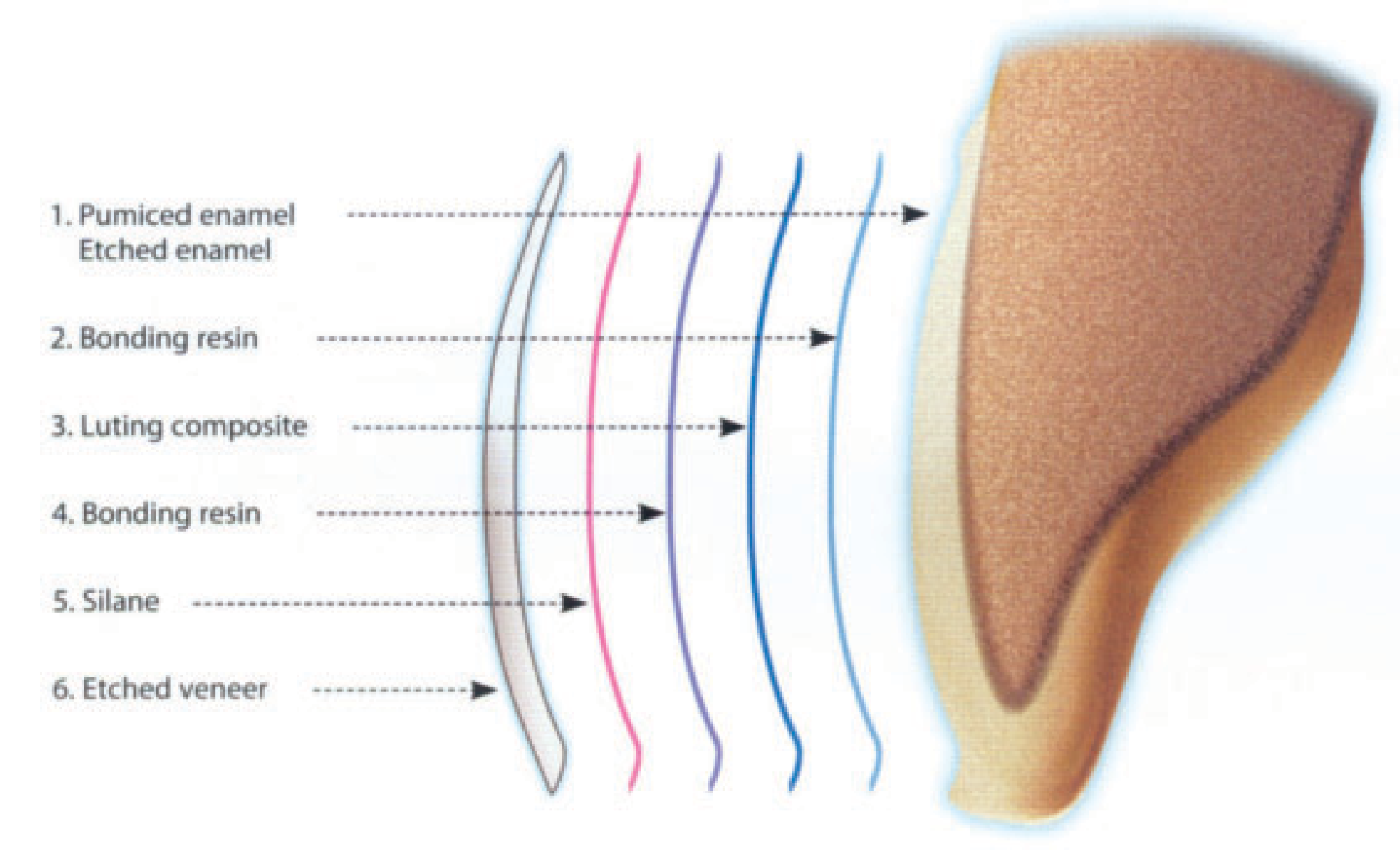
1. Pumiced enamel
Etched enamel
2. Bonding resin
3. Luting composite
4. Bonding resin
5. Silane
6. Etched veneer

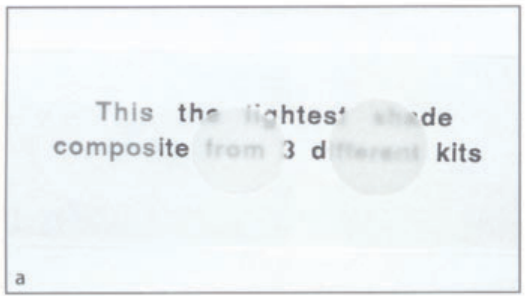
This the lightest shade
composite from 3 different kits
a


b

a

b

KERR

a

b

c

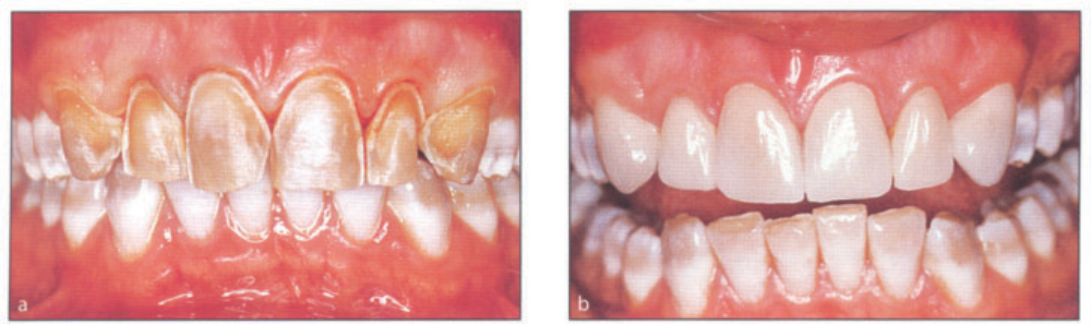
a
b

a
b
c

a

b

c

Capture 18

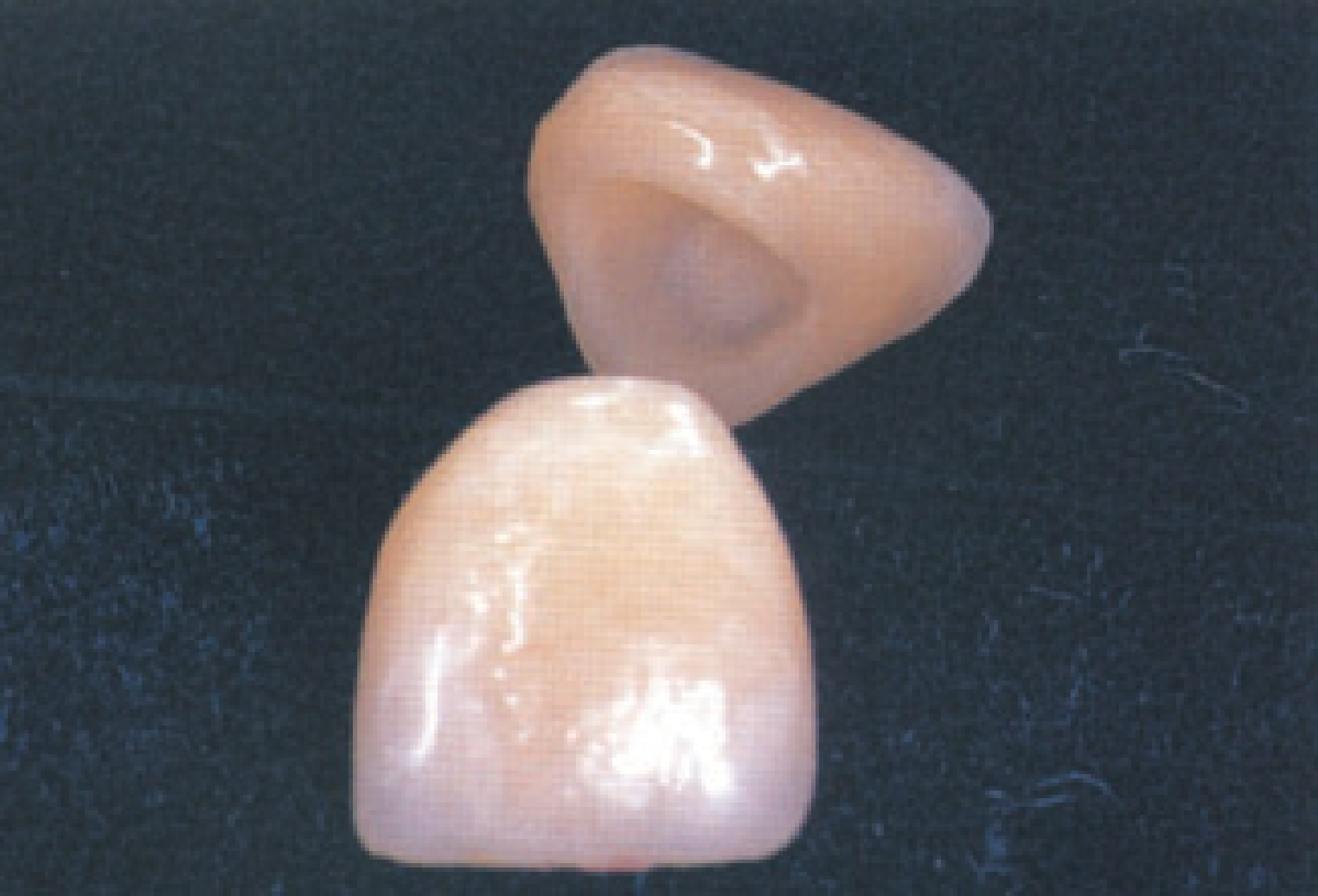

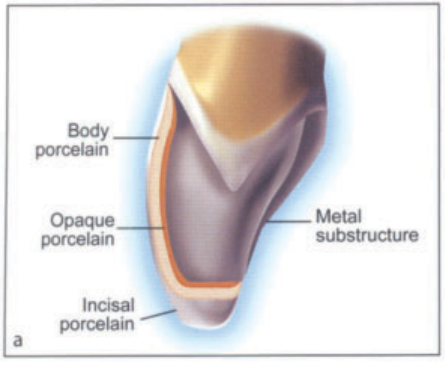
Body porcelain
Opaque porcelain
Incisal porcelain
Metal substructure
a

b

c

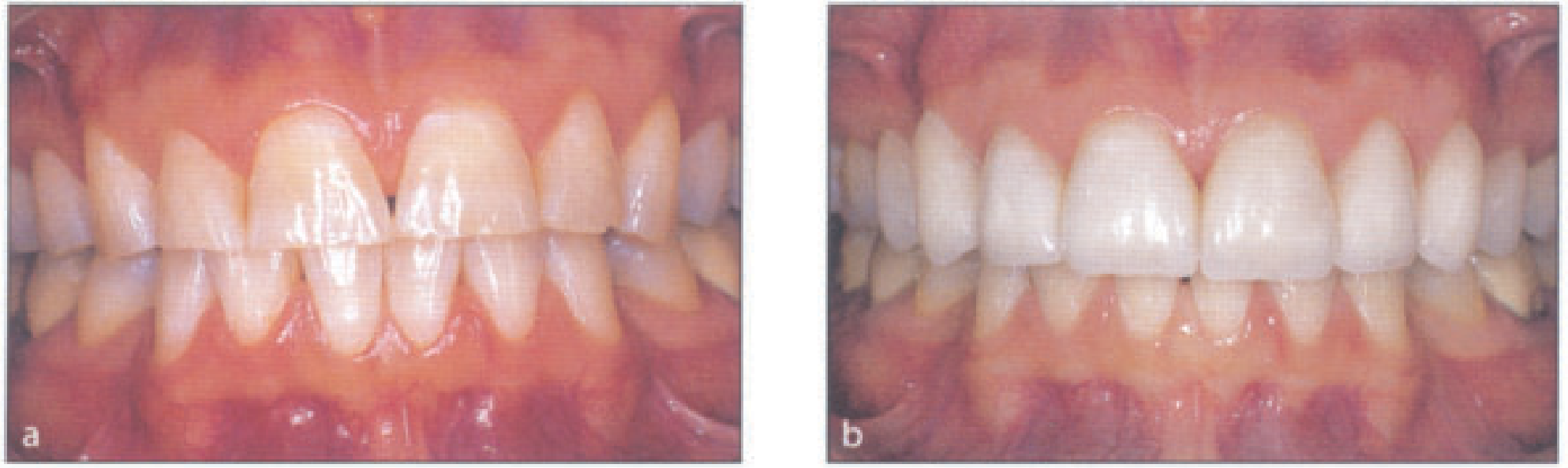
a
b

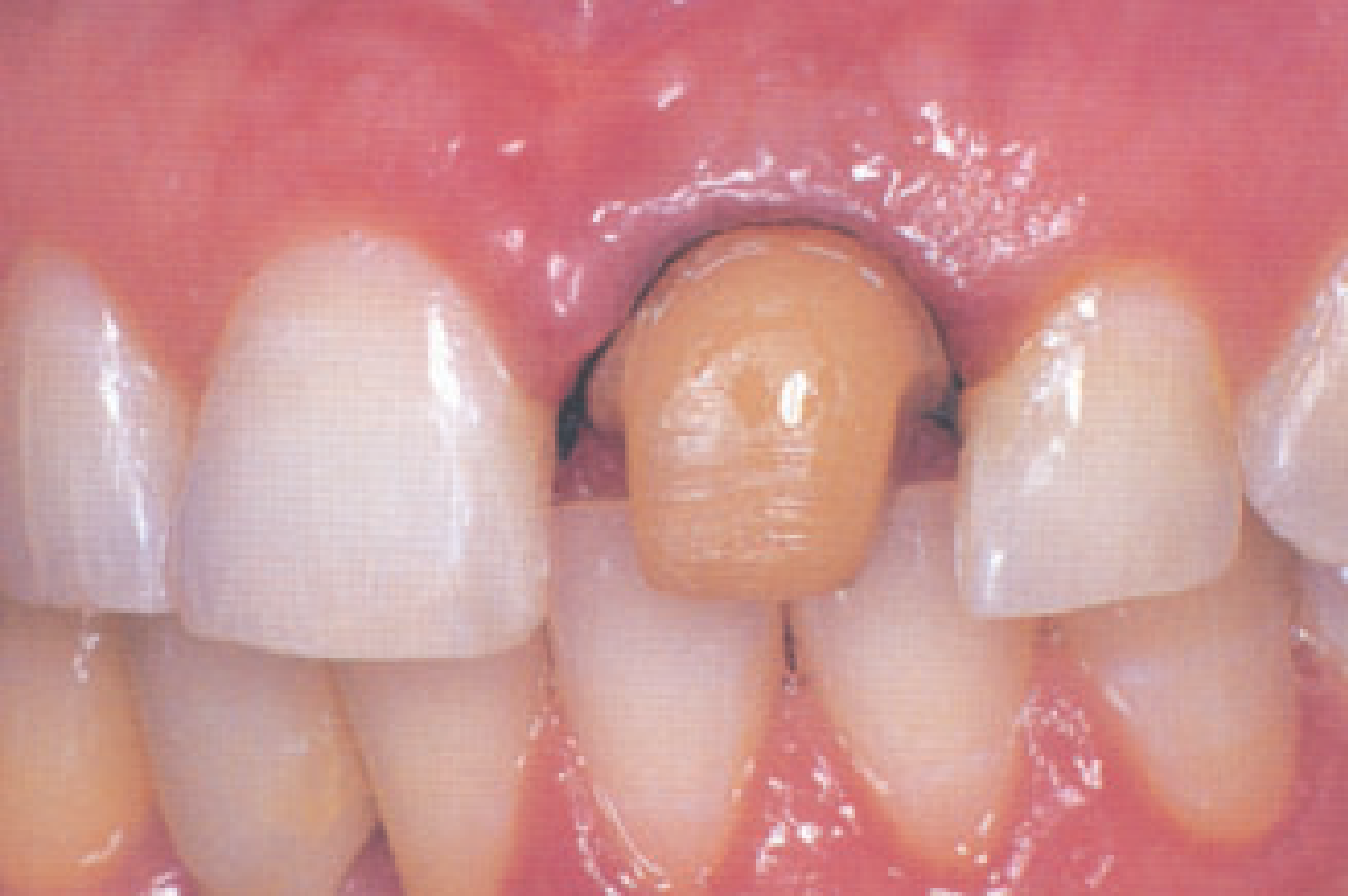

a
b
c

a

b

a

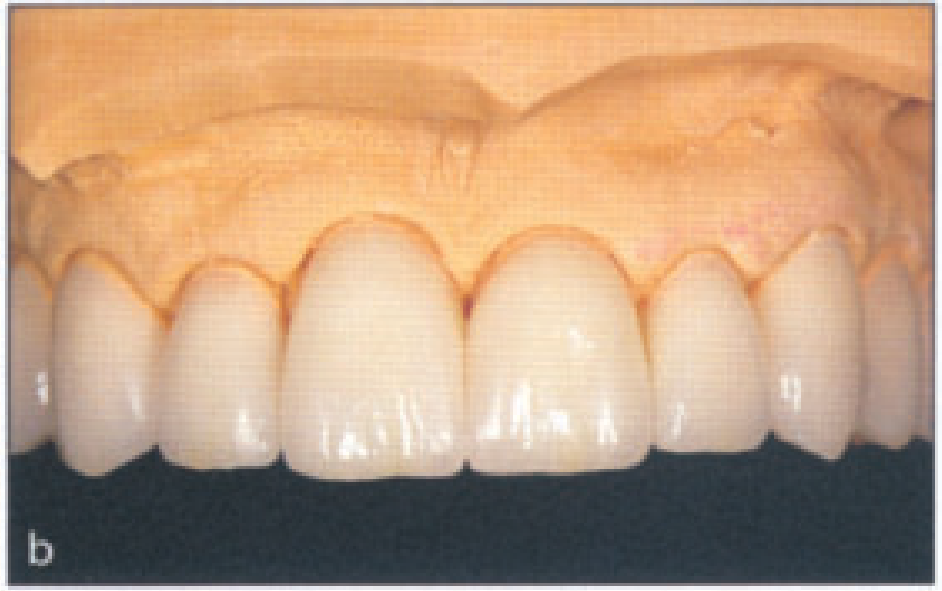
b

a

b

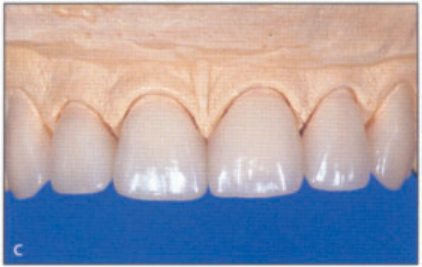
c

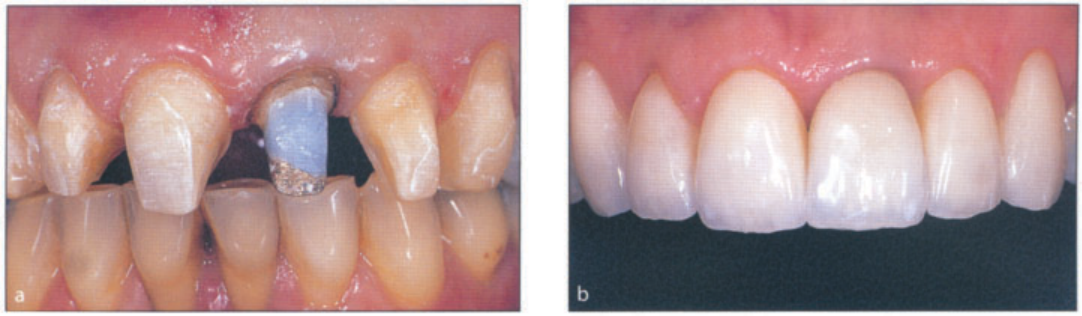
a
b

a
b
c

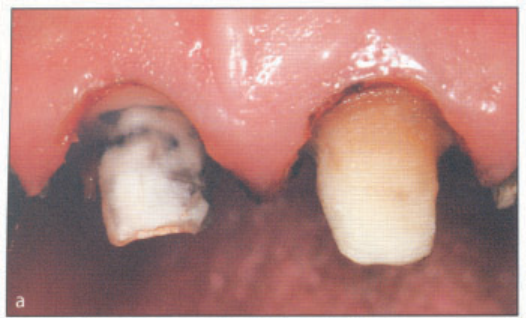
a

b

a

b

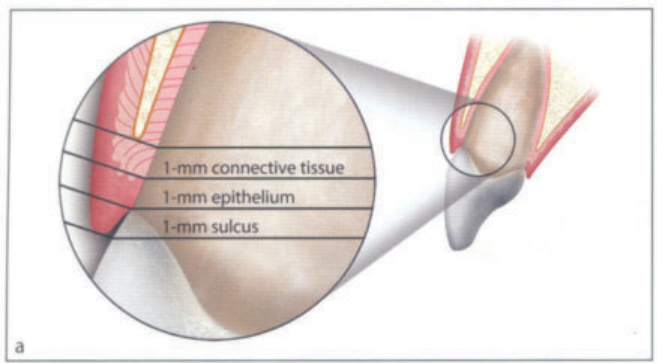
1-mm connective tissue
1-mm epithelium
1-mm sulcus
a

b

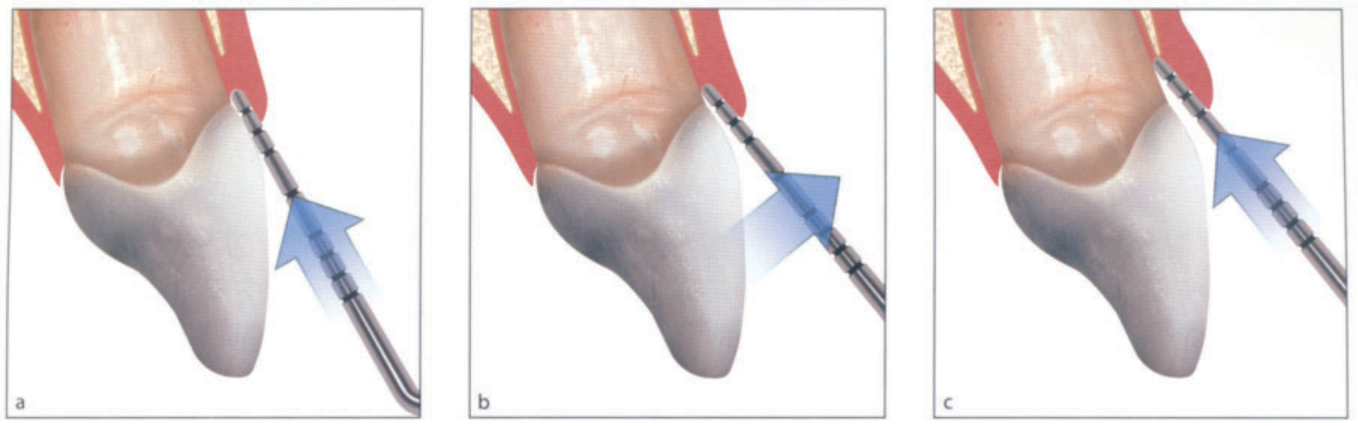
a
b
c

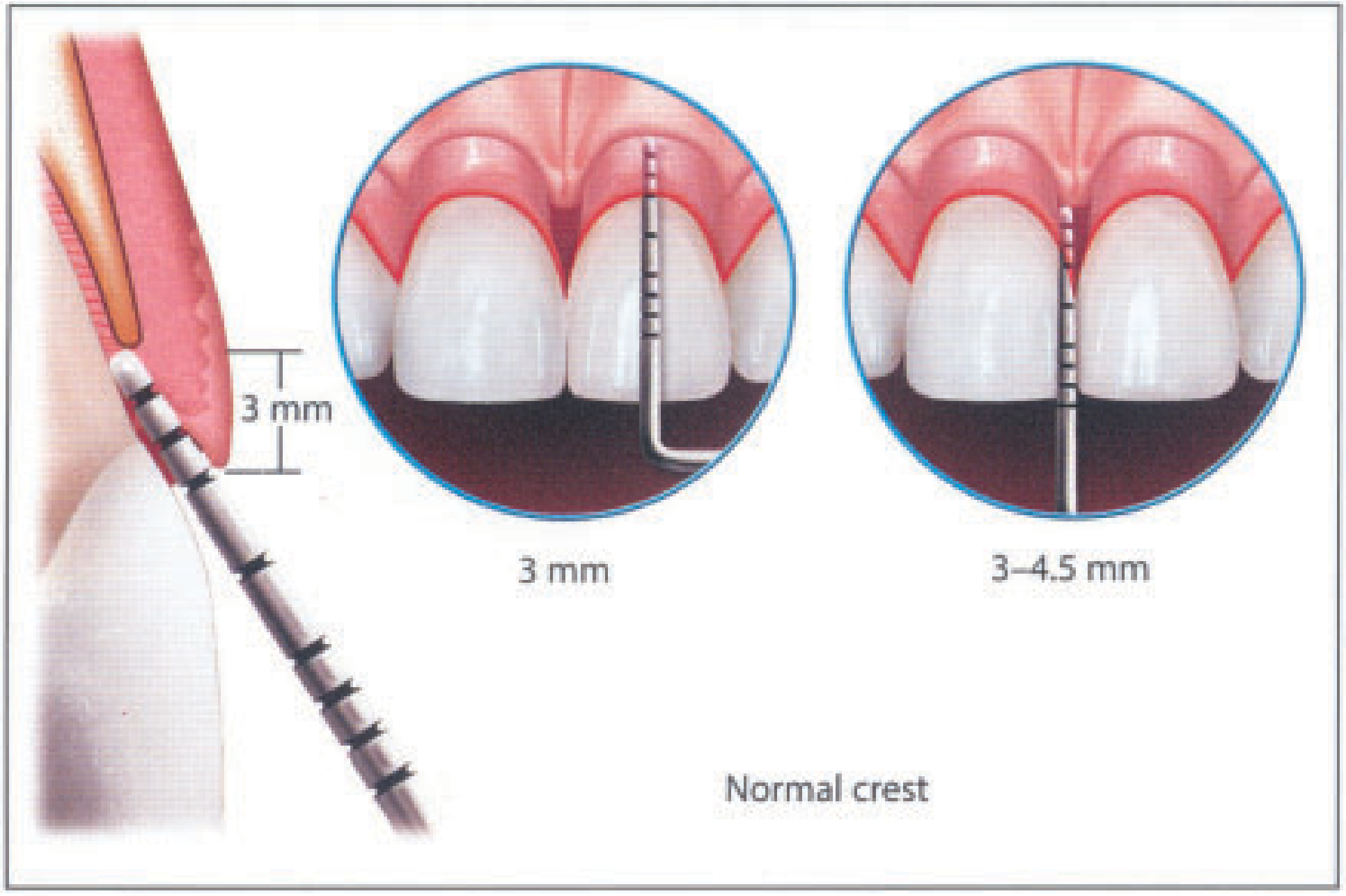
3 mm
3 mm
3–4.5 mm
Normal crest

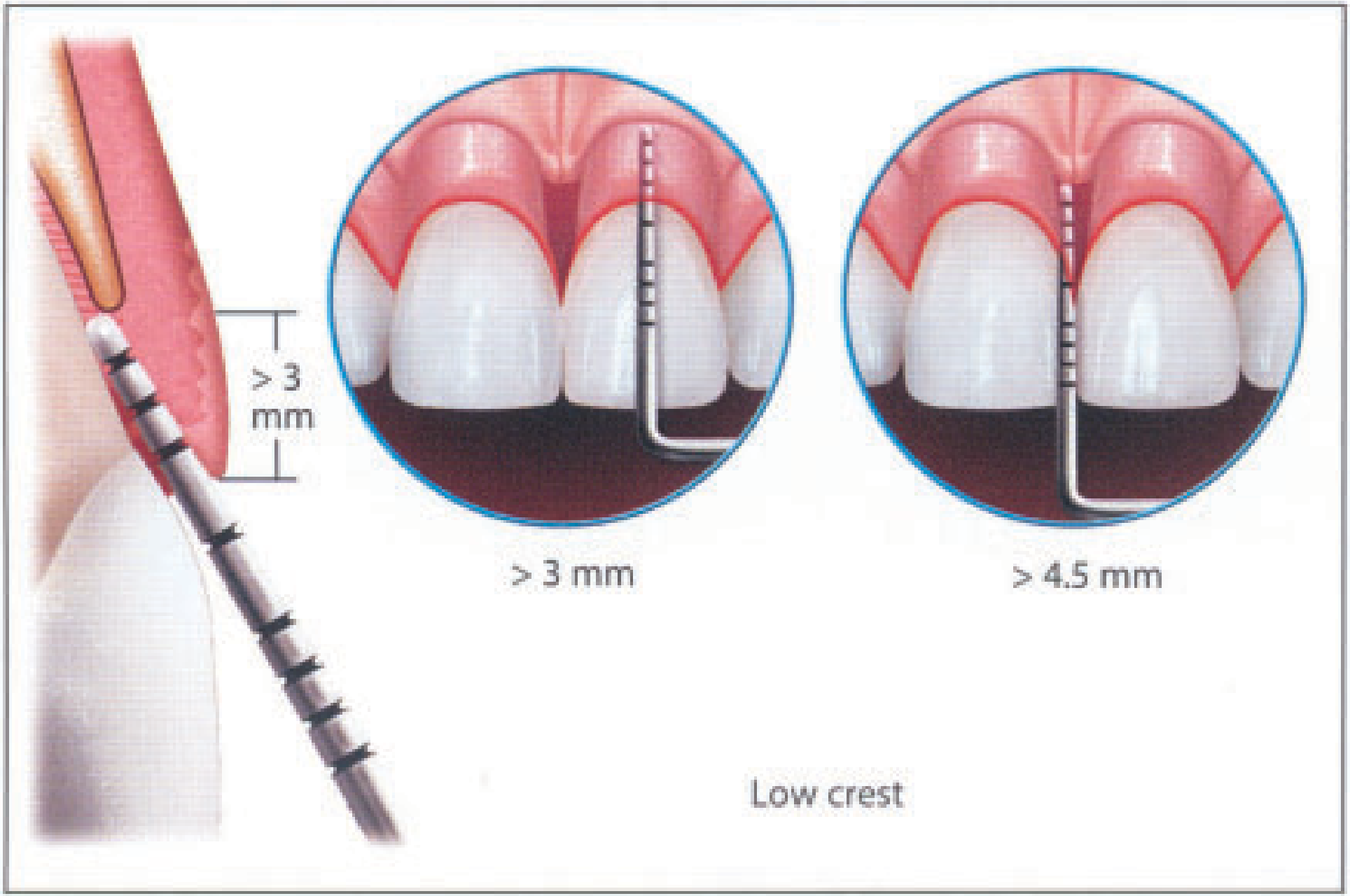
> 3
mm
> 3 mm
> 4.5 mm
Low crest

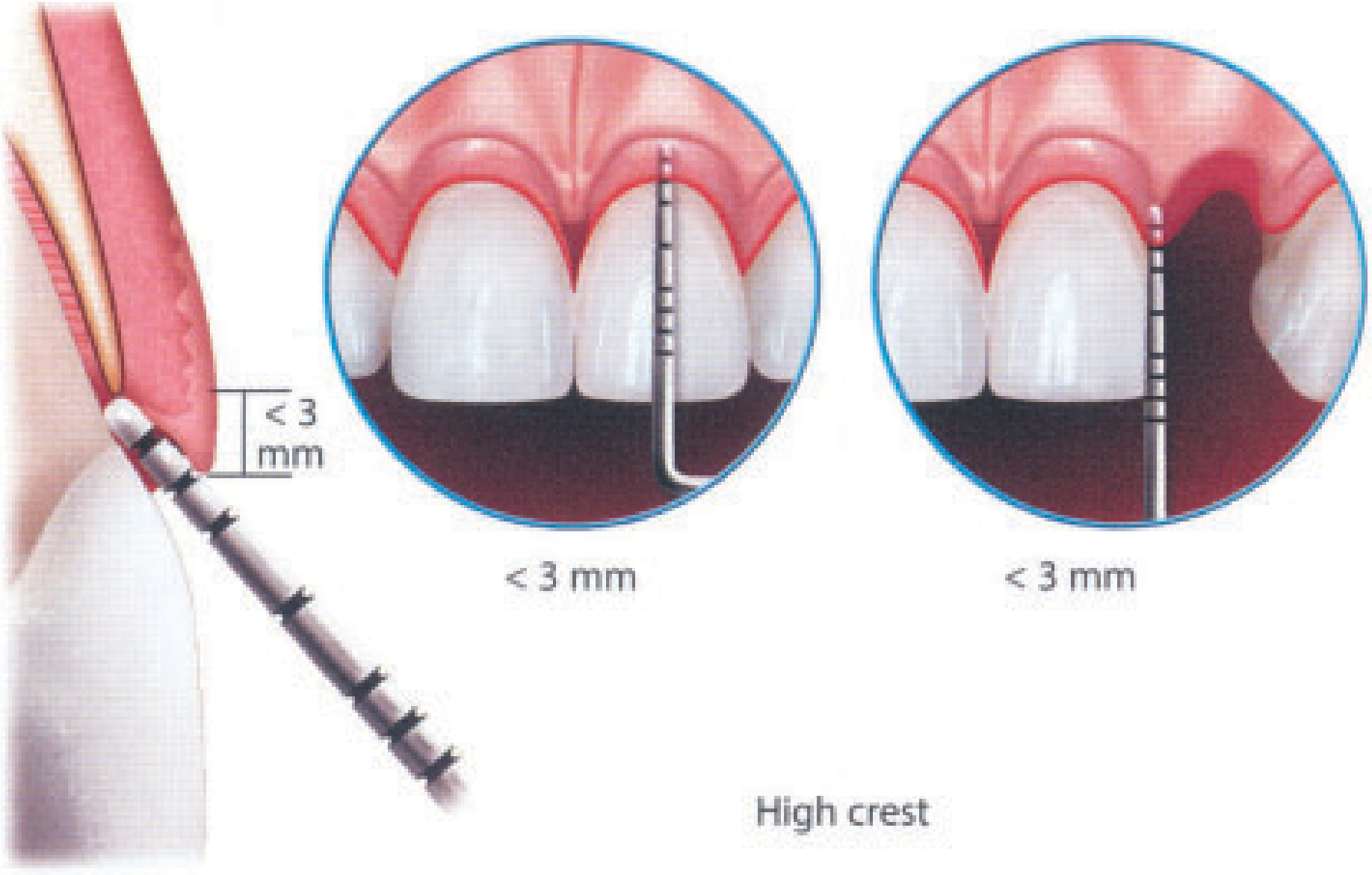
< 3
mm
< 3 mm
< 3 mm
High crest

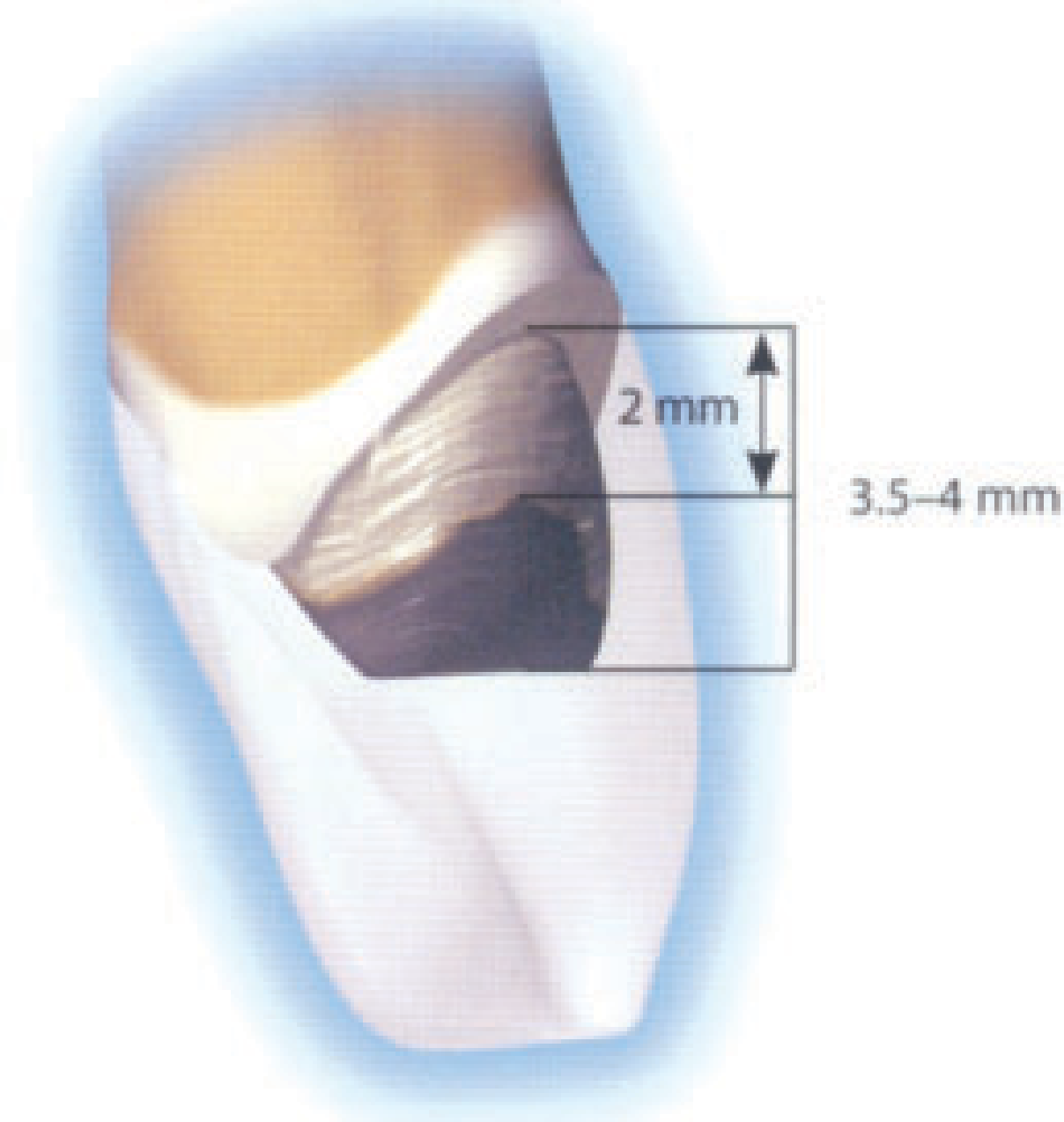
2 mm
3.5–4 mm

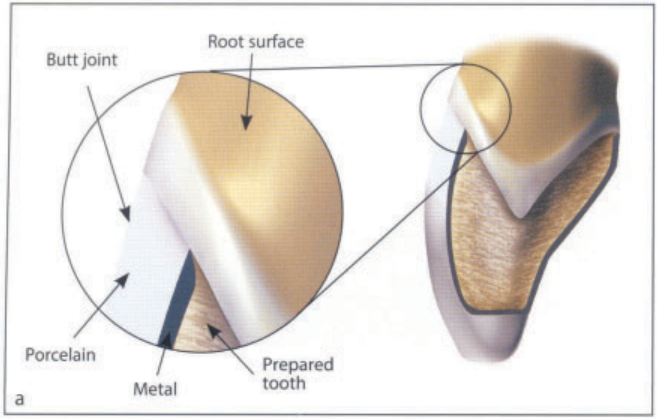
Butt joint
Root surface
Porcelain
Metal
Prepared tooth
a

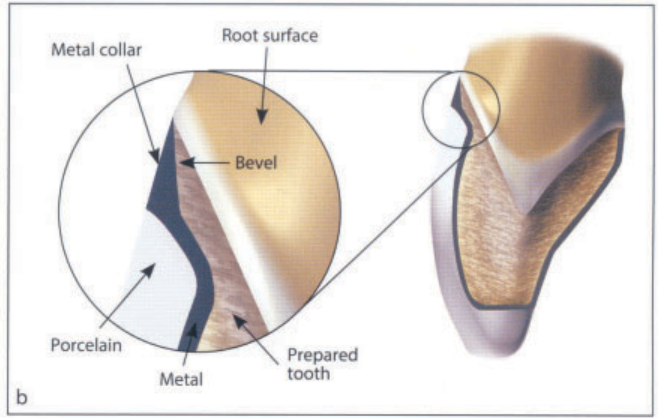
Metal collar
Root surface
Bevel
Porcelain
Metal
Prepared tooth
b

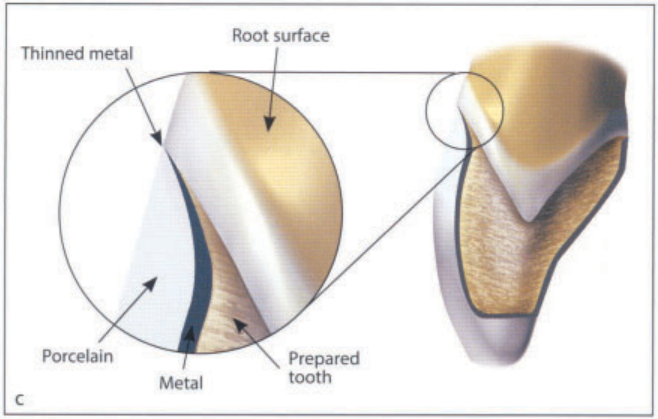
Thinned metal
Root surface
Porcelain
Metal
Prepared tooth
c

a

b

c

a

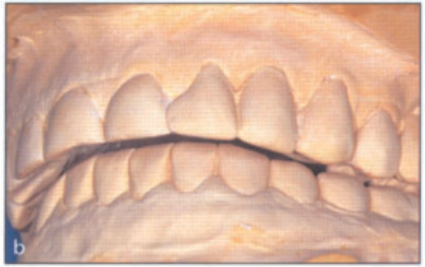
b

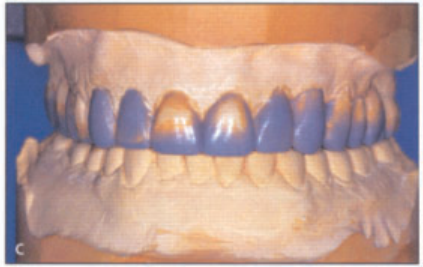
c

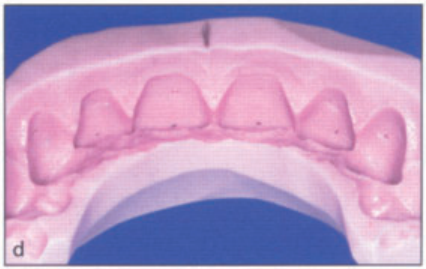
d

e

f

g

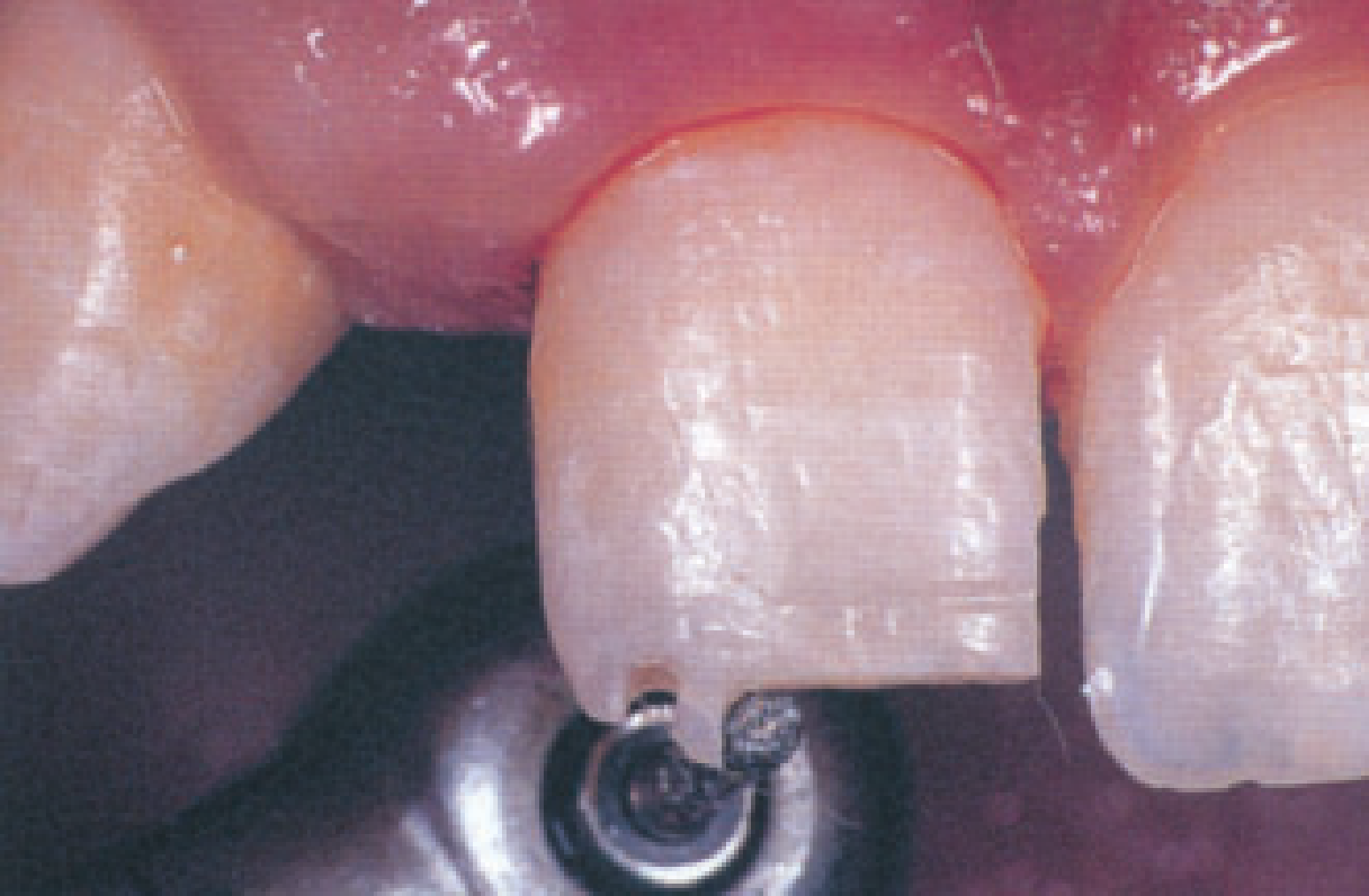

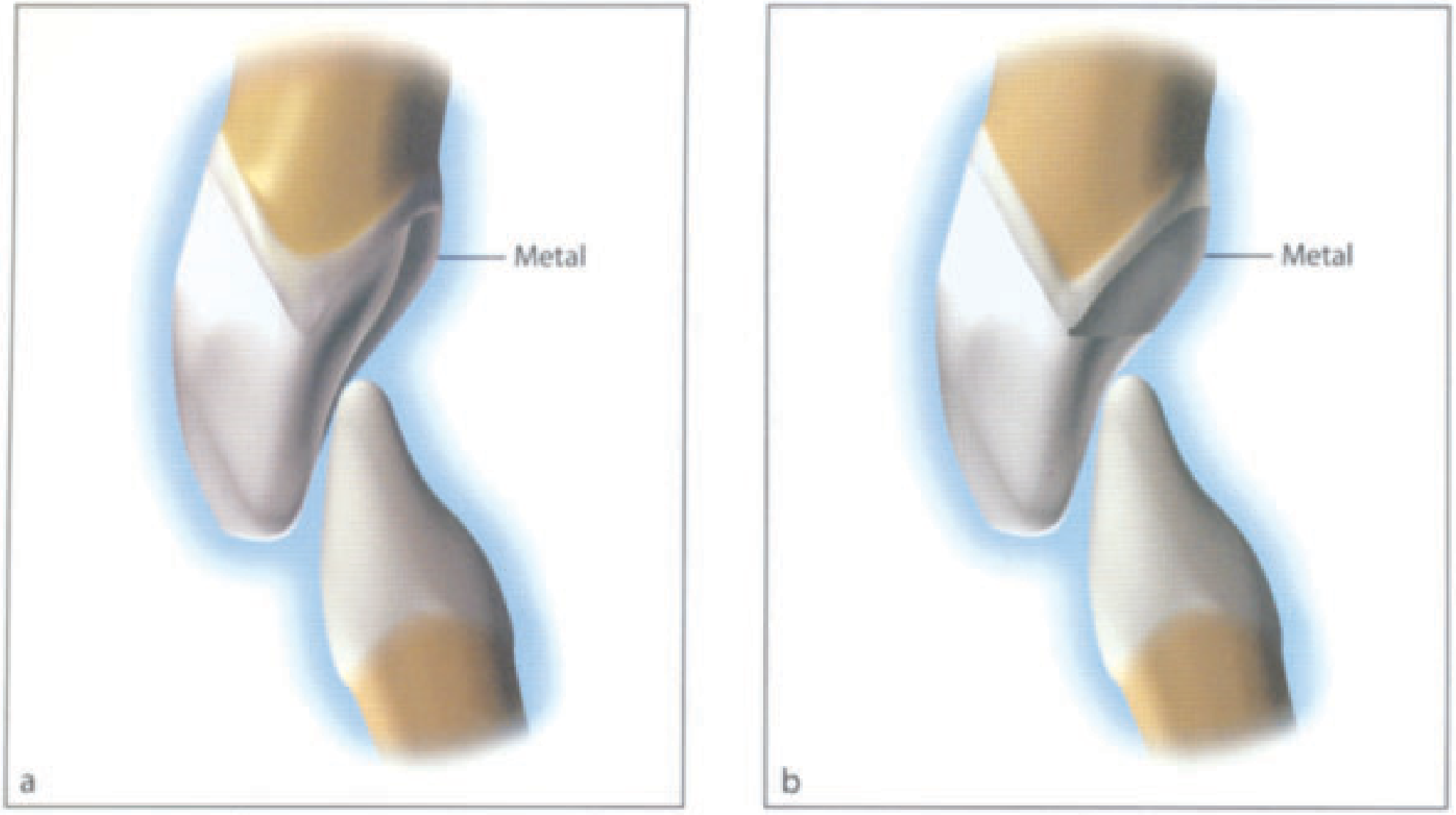
Metal
a
Metal
b

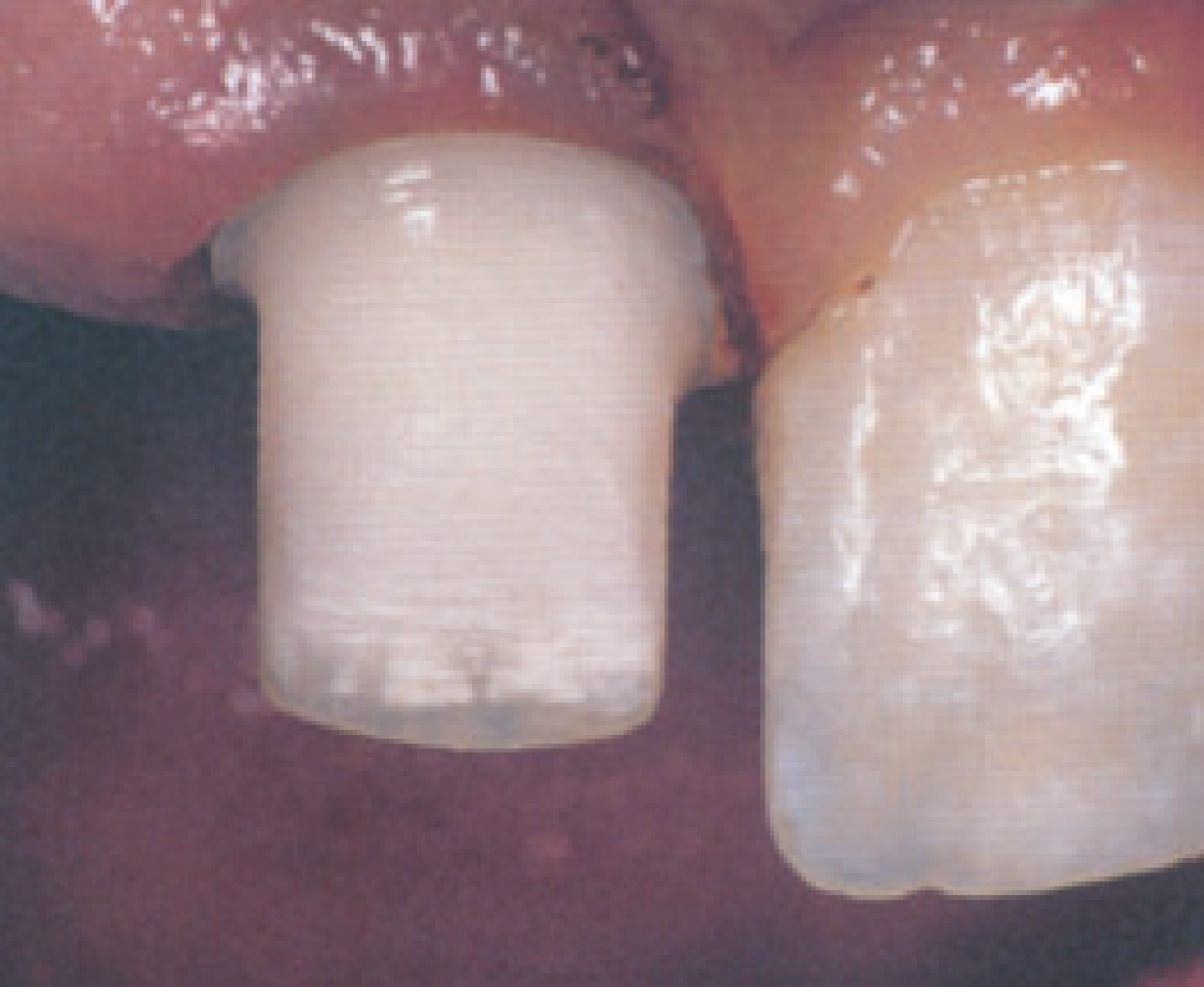

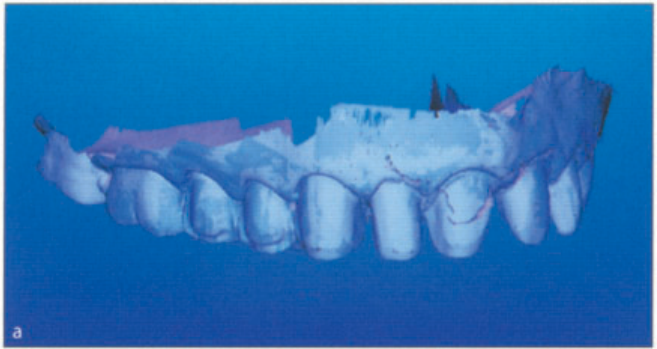
a

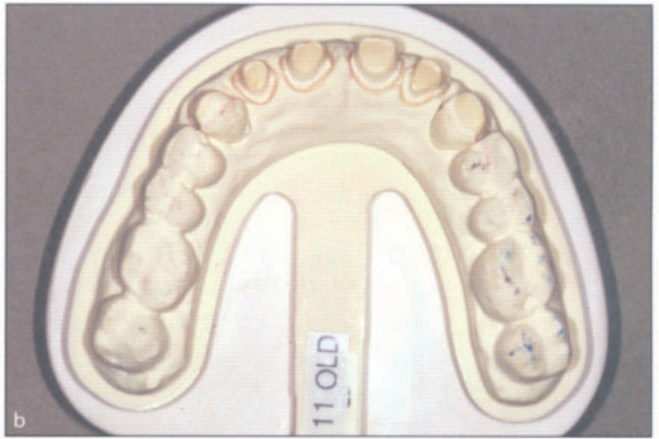
11 OLD
b

3ND

Capture 19

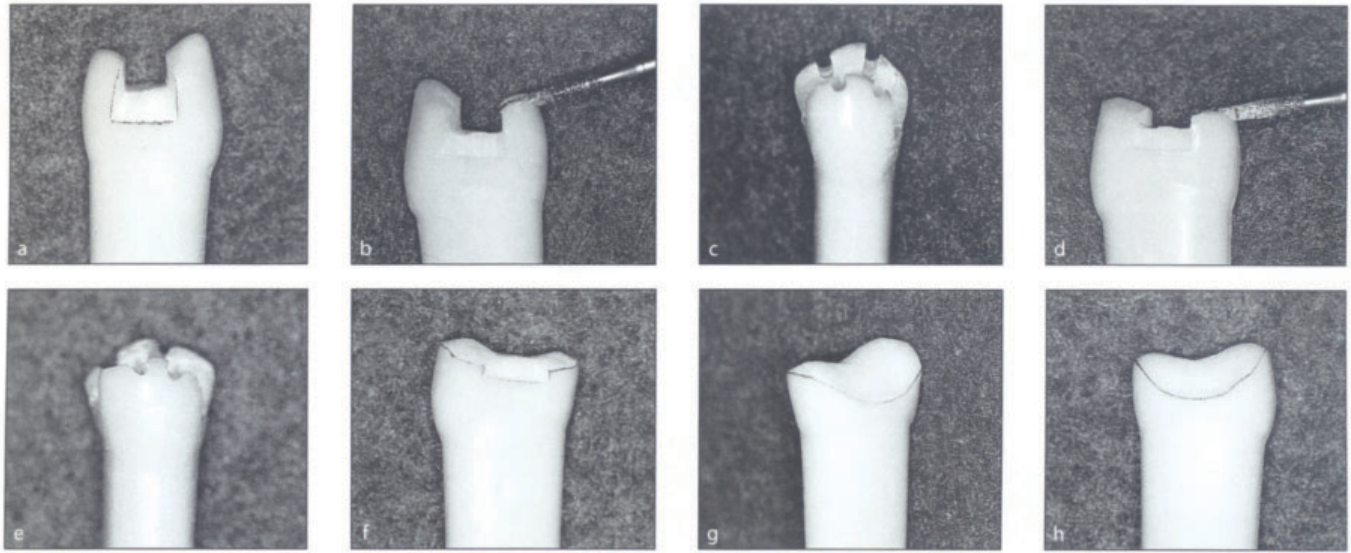
a
b
c
d
e
f
g
h

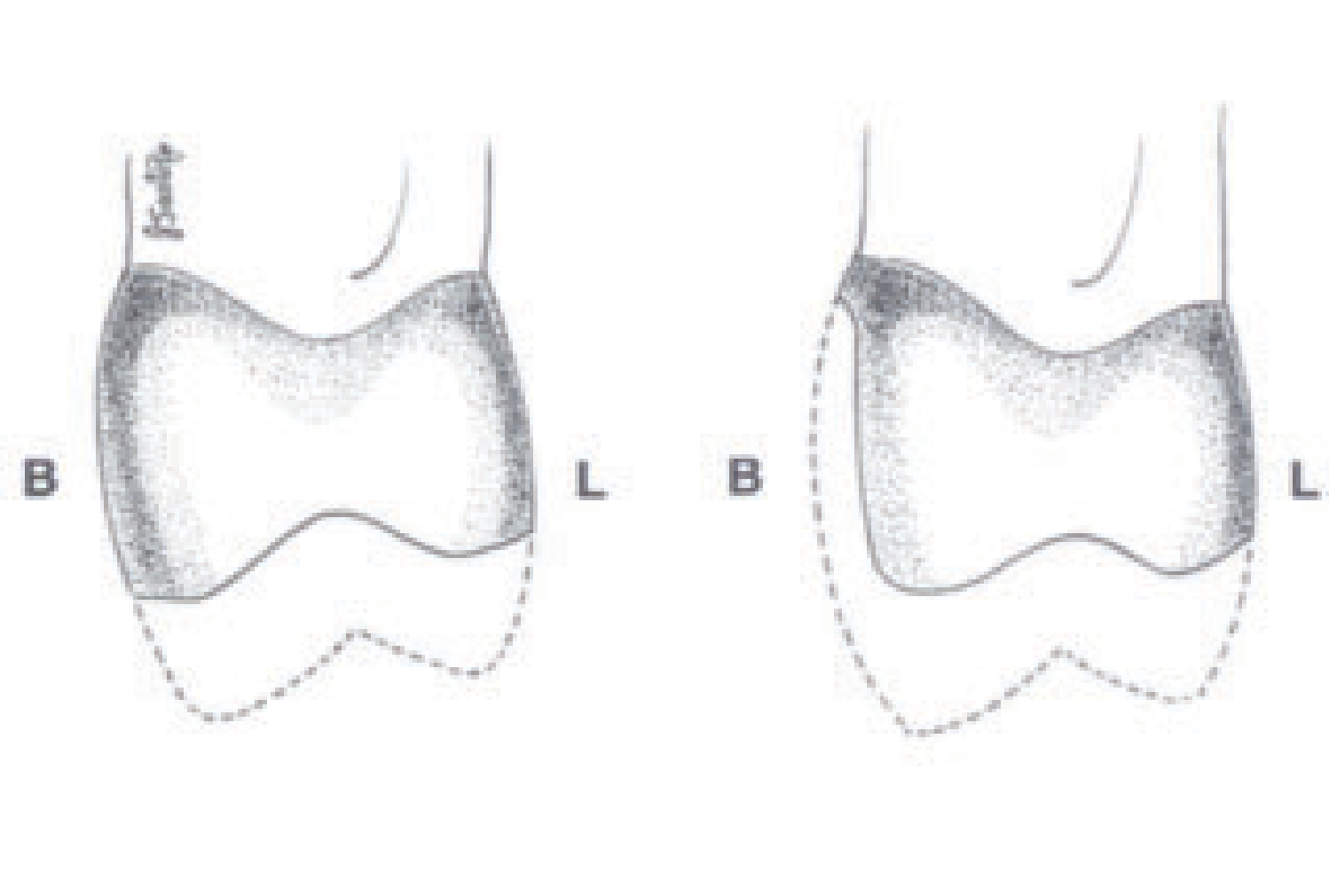
B
L
B
L

a

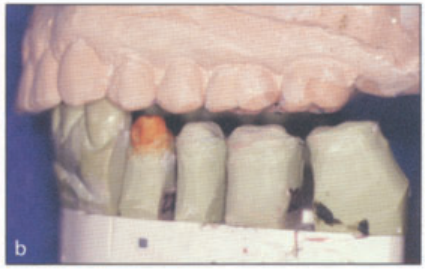
b

c

d

e

f

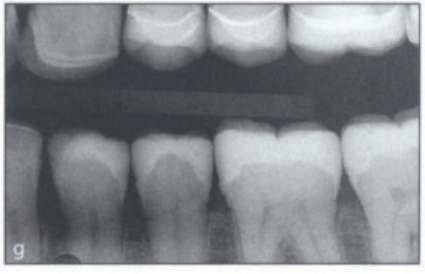
g

a

b

c

d

a

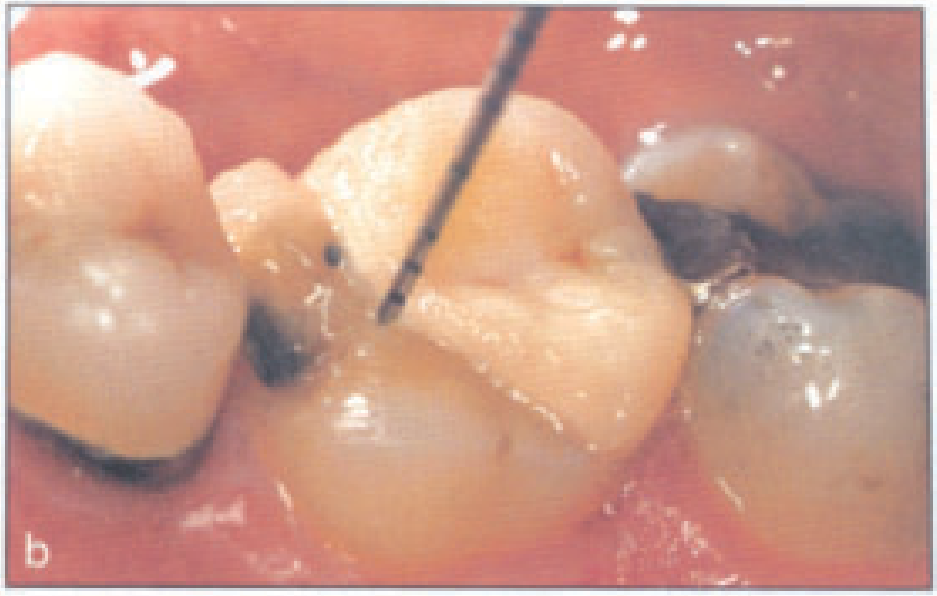
b

a

b

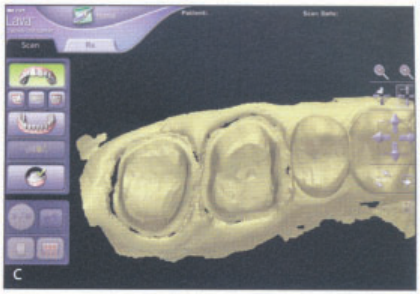
c

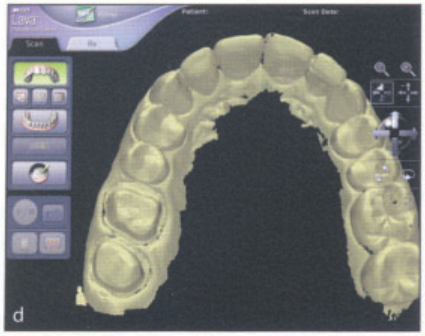
d

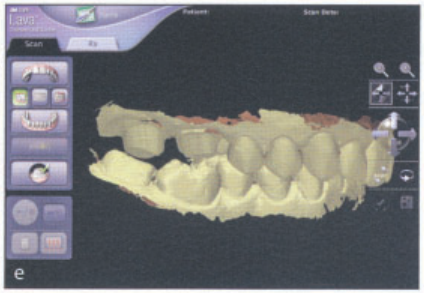
e

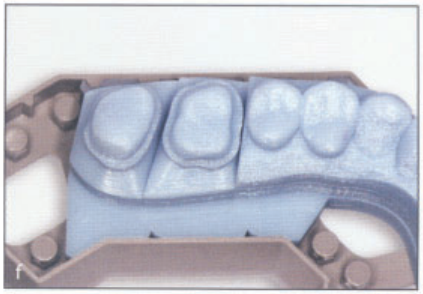
f

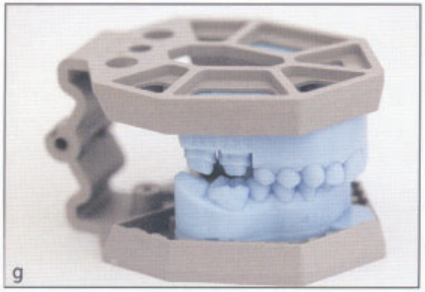
g

h

i

j

iTero
iTero

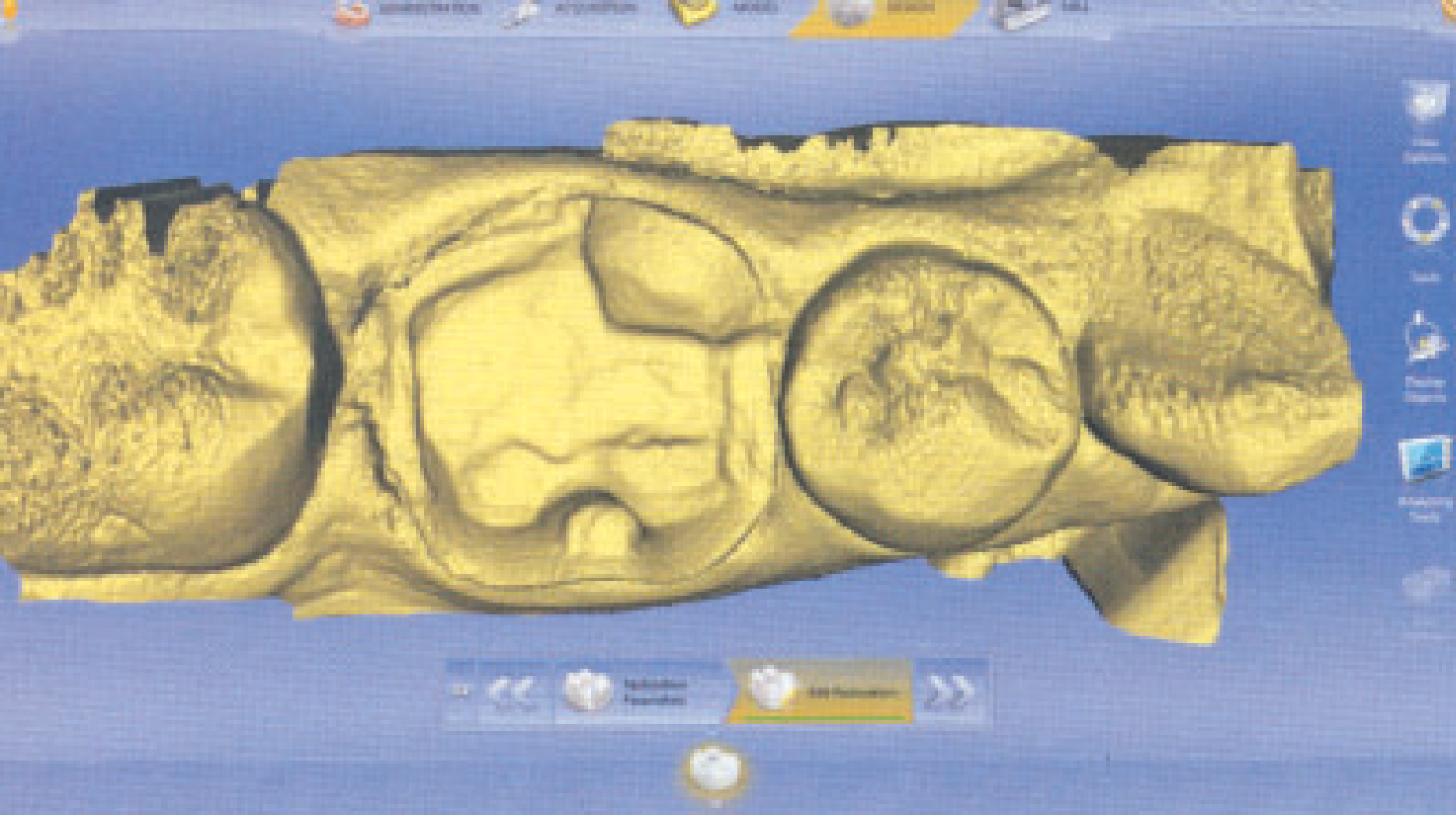

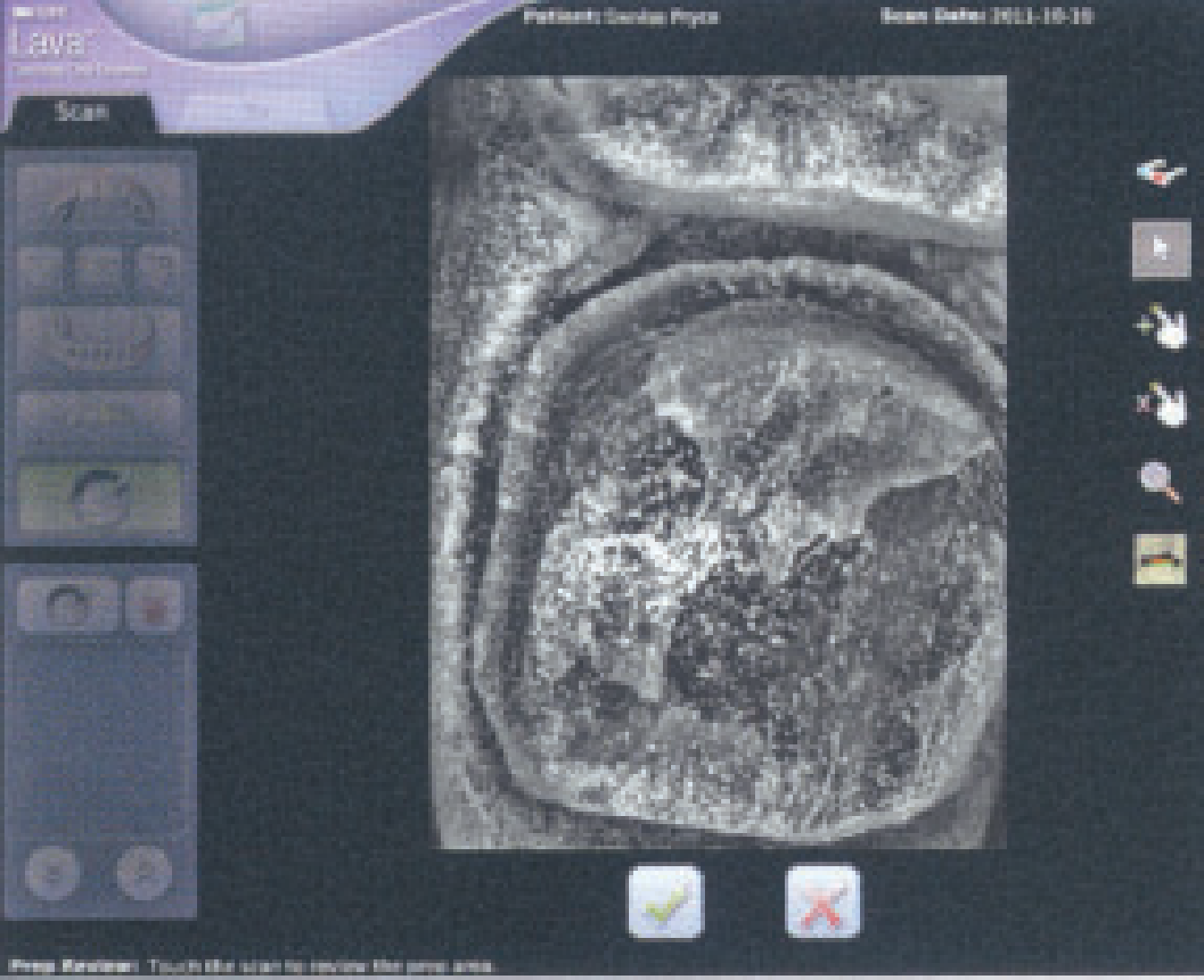
Patient: Sandip Pryce
Scan Date: 2011-10-10
Scan
Prep Review: Touch the scan to review the prep area.

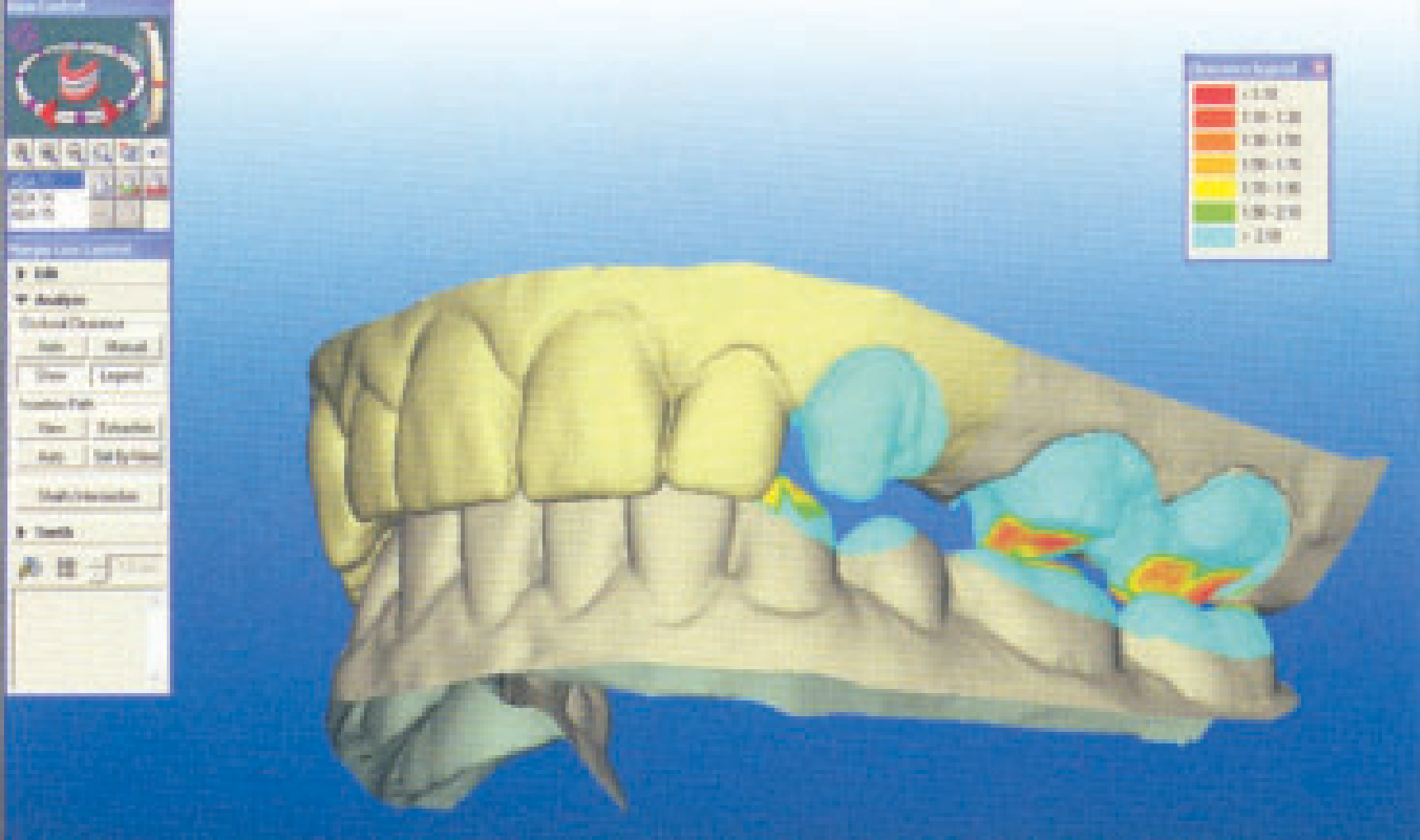

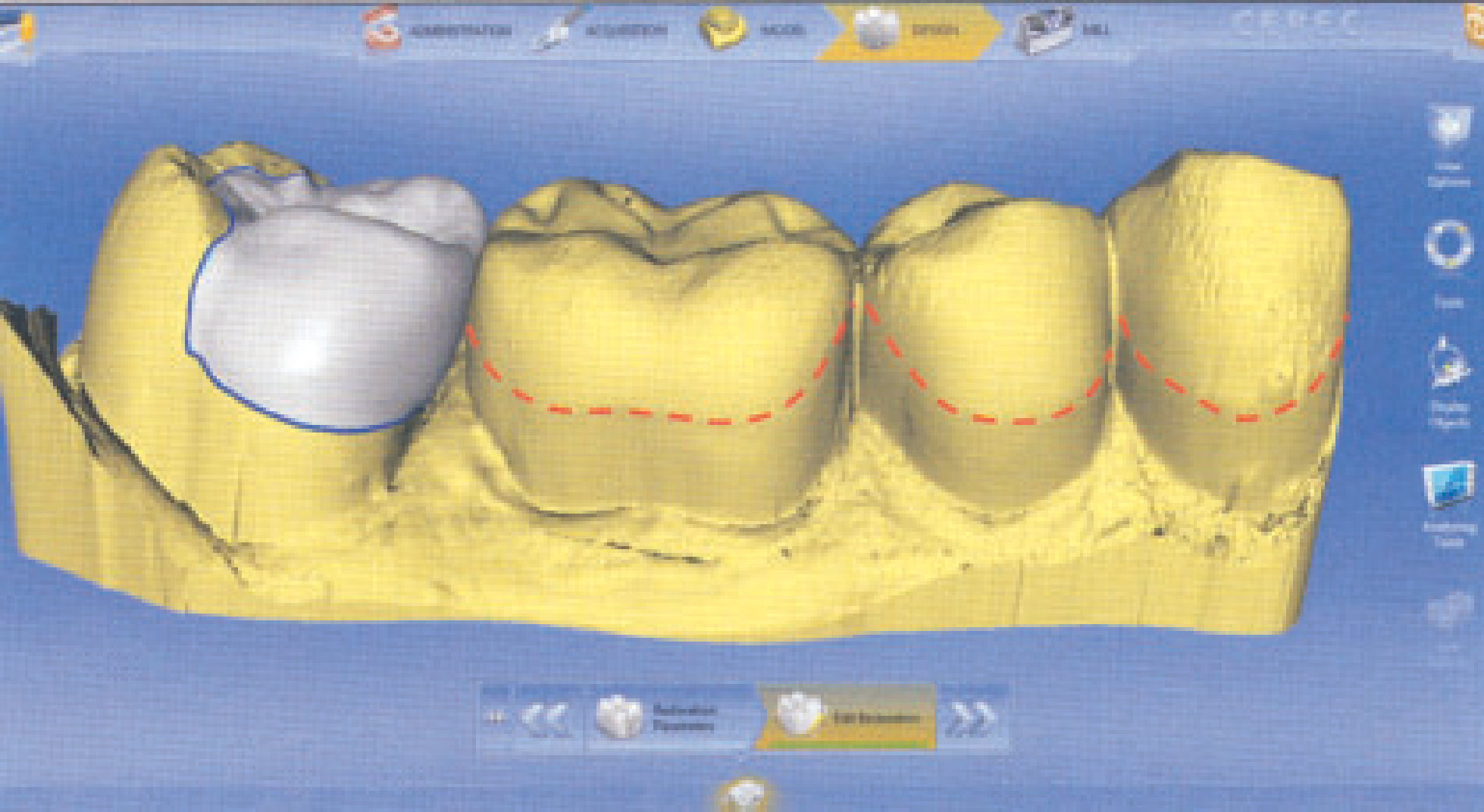

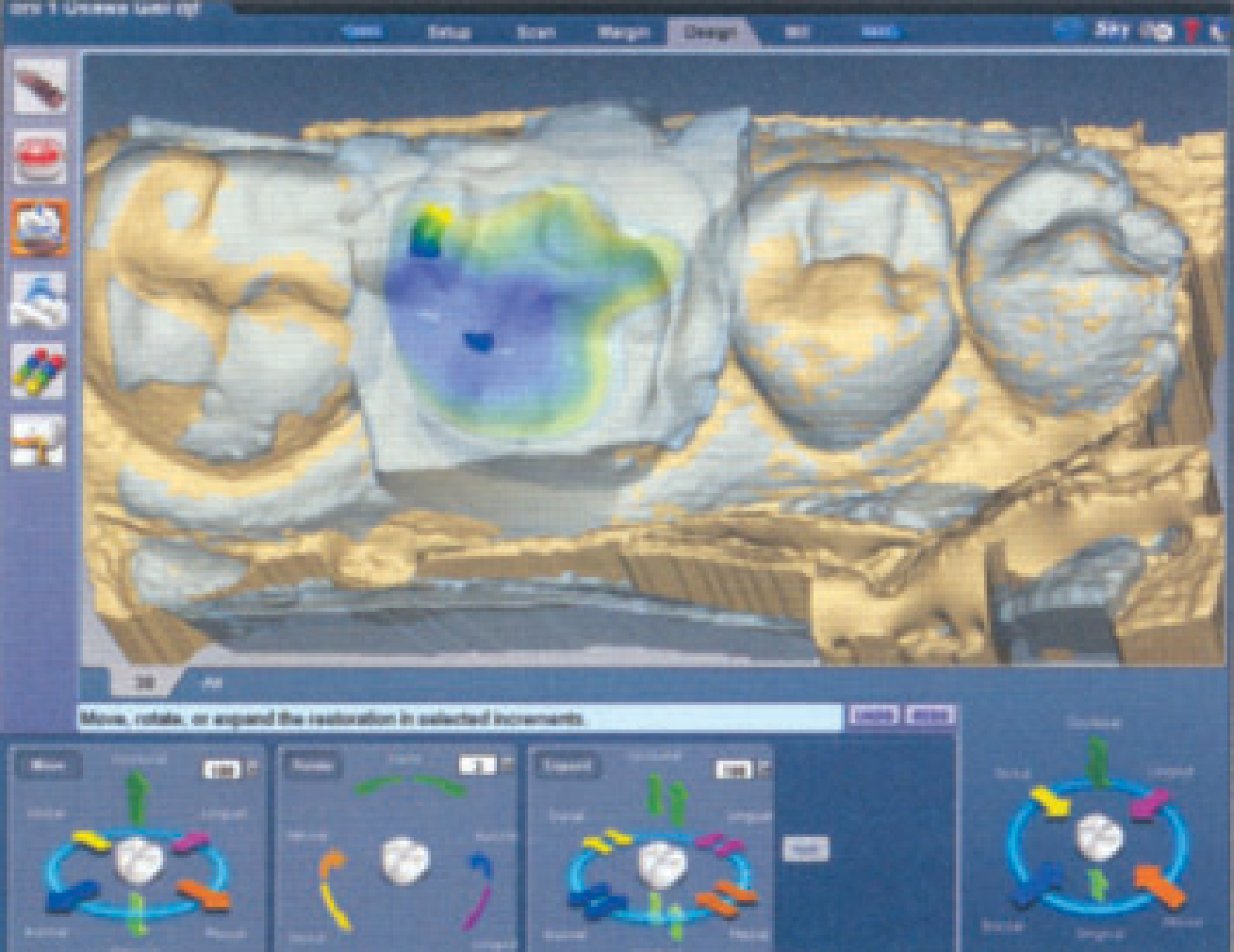
Setup
Scan
Margin
Design
Move, rotate, or expand the restoration in selected increments.

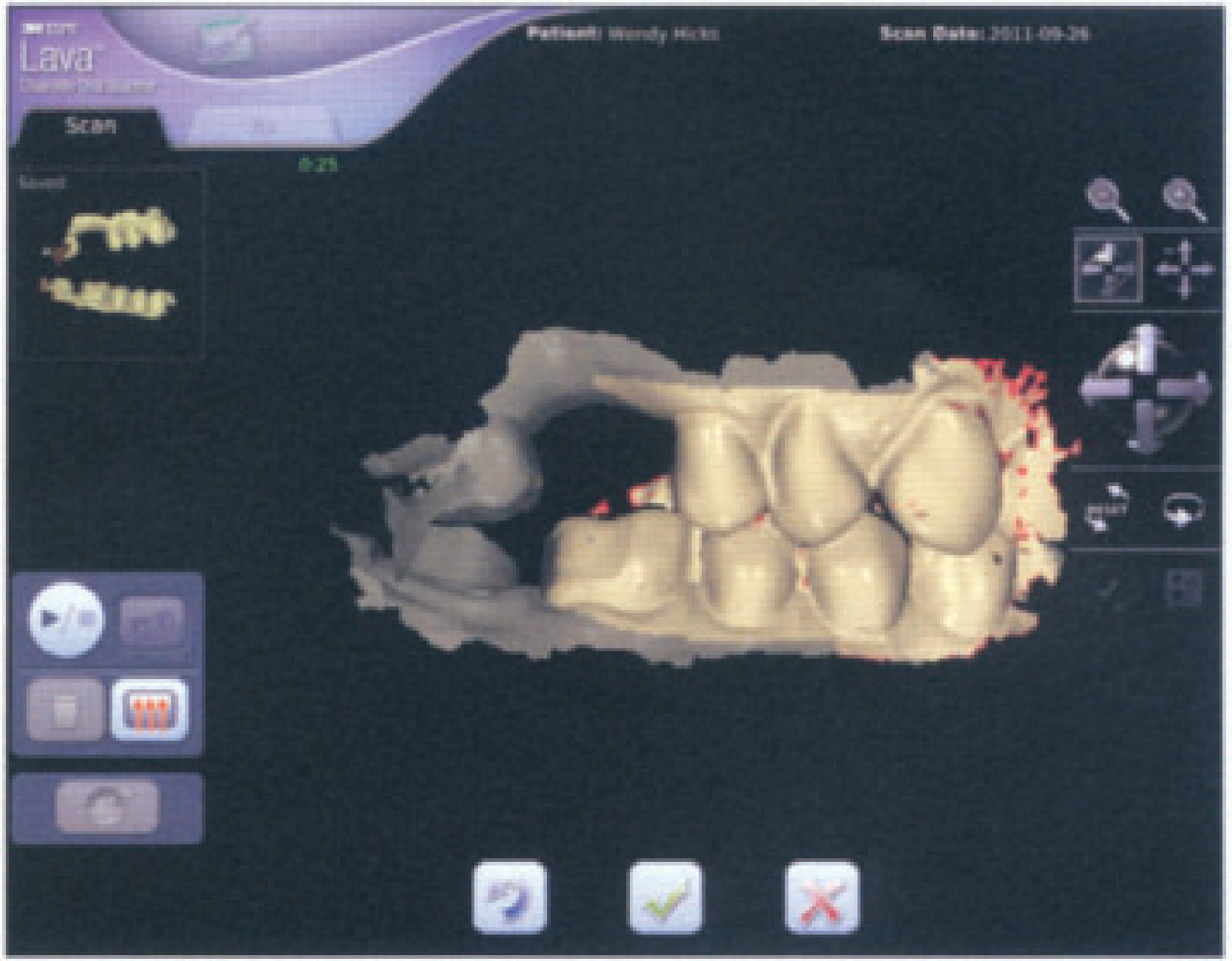
Lava
Scan
Patient: Wendy Hicks
Scan Date: 2011-09-26
0:25

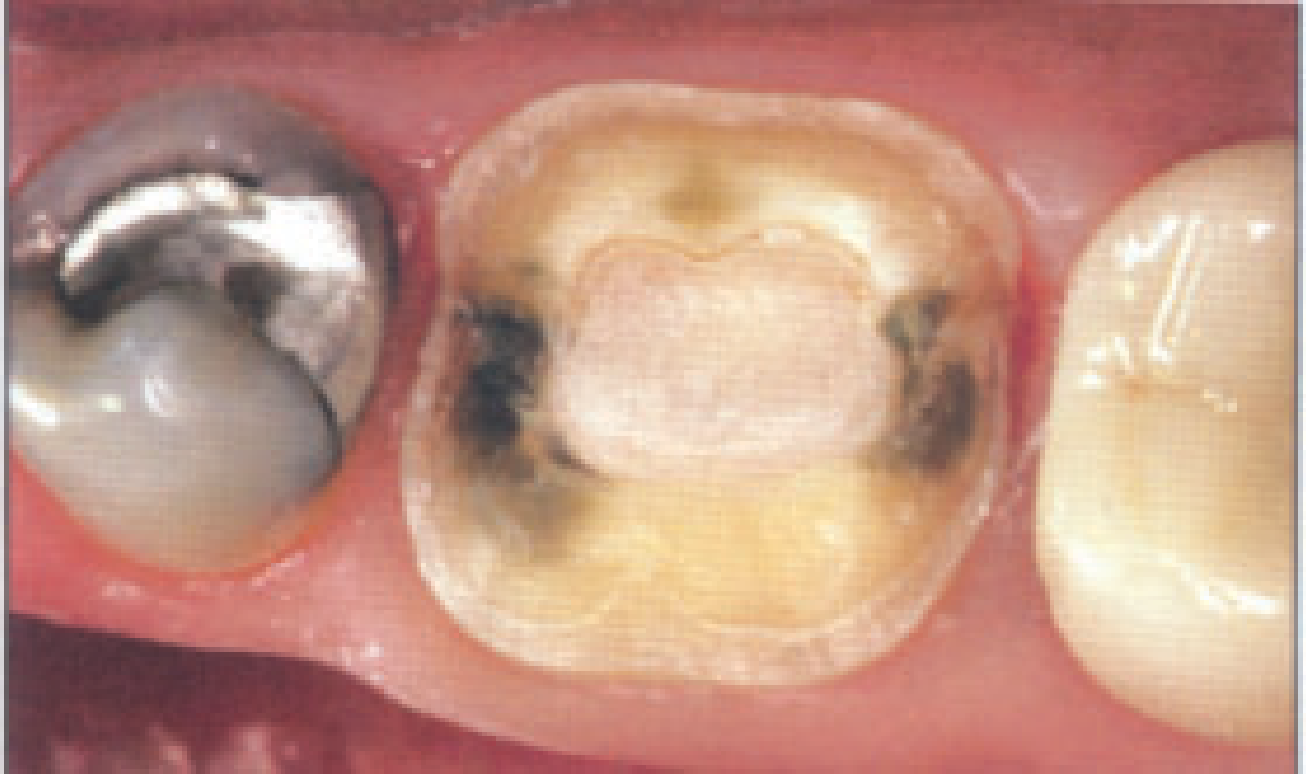

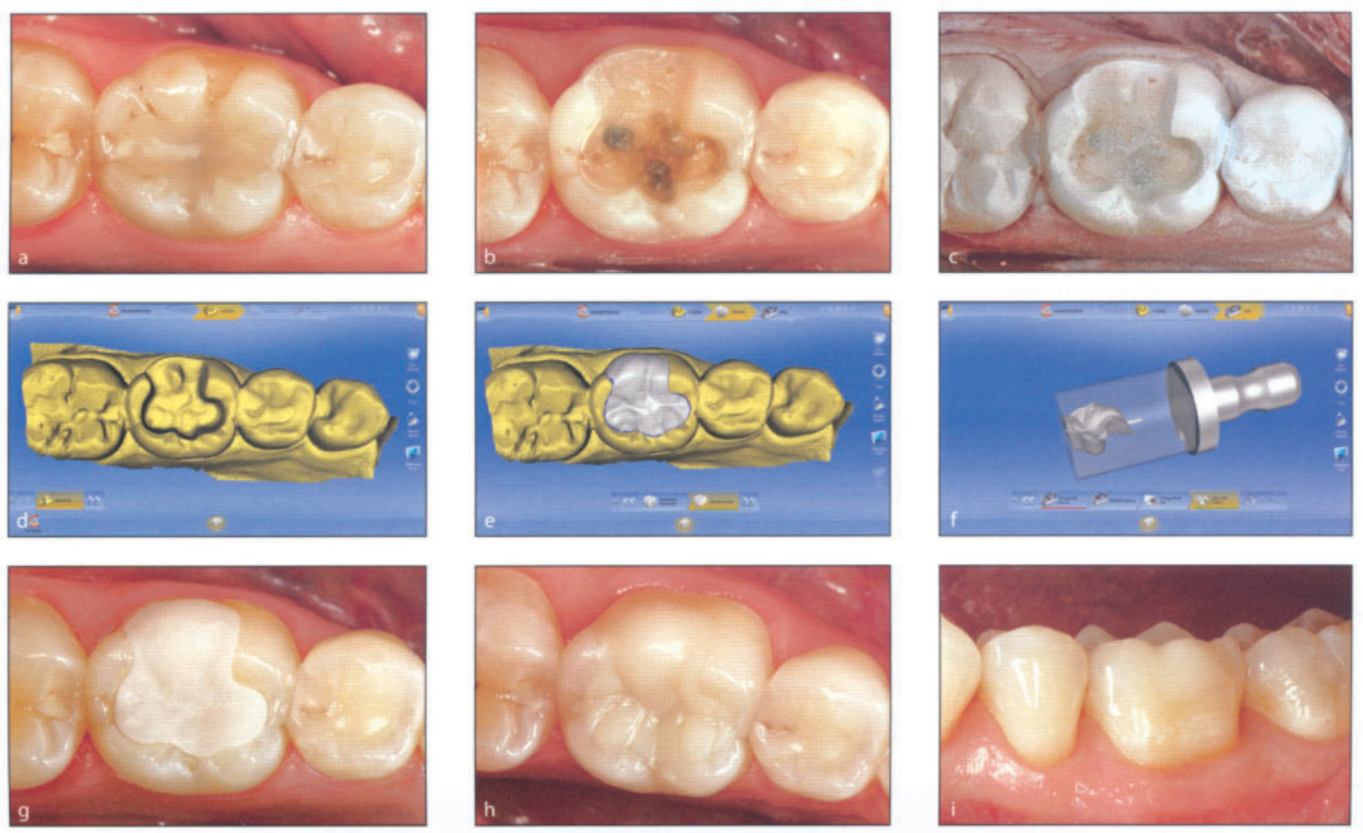
a
b
c
d
e
f
g
h
i